

TABLE OF CONTENTS

CHAPTER

1	Brain SPECT Imaging: An Introduction	5
2	Images, Normal and Abnormal <i>How SPECT is interpreted and rated</i>	10
3	Images of Functional Neuroanatomy	13
4	Images of Strokes <i>Compelling Reasons Not to Smoke</i>	20
5	Images of Dementia versus Pseudodementia	24
6	Images of Brain Trauma <i>Wear a helmet, Avoid fights, No headers in soccer, Wear your seatbelt, Play golf instead of football</i>	28
7	Images of Depression	39
8	Images of Bipolar Disorder and Schizophrenia	45
9	Images of the Ring of Fire <i>Angry, Moody, and Oppositional</i>	50
10	Images of PMS <i>Is it real? You bet!</i>	56
11	Images of Anxiety	67
12	Images of Attention Deficit Disorder	71
13	Images of Obsessive Compulsive Spectrum Disorders	79
14	Images of Violence	85
15	Images of Alcohol and Drug Abuse <i>Brain Pollution and the Real Reason You Shouldn't Use</i>	94
16	Images of Treatment <i>Hope for Healing</i>	105

Images Into Human Behavior

A Brain SPECT Atlas

Daniel G. Amen, MD

**Brain Imaging Division
The Amen Clinic for Behavioral Medicine**

350 Chadbourne Road, Fairfield, CA 94585

(707) 429-7181 Fax (707) 429-8210

www.amenclinic.com

Copyright 1998 by Daniel G. Amen, M.D.
All rights reserved. No part of this book may be reproduced or transmitted
in any form or by any means without the written permission of the author.

MindWorks Press
350 Chadbourne Road
Fairfield, California 94585
(707) 429-7181 Fax (707) 429-8210

Manufactured in the United States of America
9 8 7 6 5 4 3 2

Other Books By Dr. Amen

WINDOWS INTO THE A.D.D. MIND:
Understanding and Treating Attention Deficit Disorder, Childhood Through Adulthood

FIRESTORMS IN THE BRAIN
An Inside Look at Violent Behavior

CHANGE YOUR BRAIN, CHANGE YOUR LIFE
The Breakthrough Clinically Proven Program for: Mastering Your Moods,
Conquering Anxiety and Obsessions and Taming Temper and Distractibility

BREAKING THROUGH
How To Be Effective Every Single Day Of Your Life

THE INSTRUCTION MANUAL THAT SHOULD HAVE COME WITH YOUR CHILD
New Skills for Frazzled Parents

HEALING THE CHAOS WITHIN
The Interaction Between A.D.D., Alcoholism and Growing Up In an Alcoholic Home

MINDCOACH FOR KIDS
Teaching Kids and Teens To Think Positive and Feel Good

WOULD YOU GIVE TWO MINUTES A DAY FOR A LIFETIME OF LOVE?

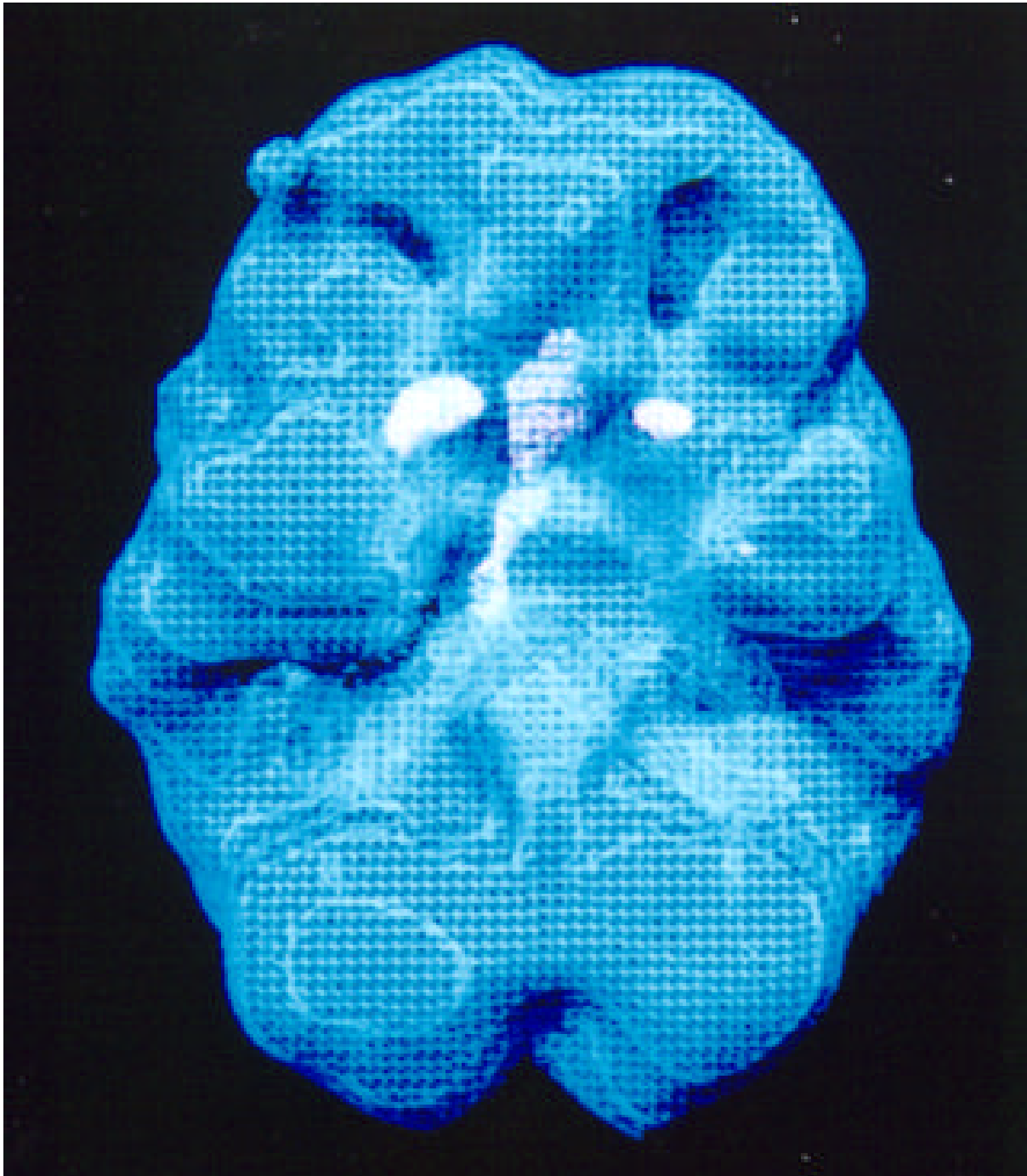
TEN STEPS TO BUILDING VALUES WITHIN CHILDREN

A TEENAGER'S GUIDE TO A.D.D.

A CHILD'S GUIDE TO A.D.D.

Confidentiality is essential to psychiatric practice. All case descriptions in this book, therefore, have been altered to preserve the anonymity of my patients without distorting the essentials of their stories.

The information offered in this book is not intended to be a substitute for the advice and counsel of your personal physician. Consult with your physician before making any medical changes.



**The Author's Brain.
A bit of anxiety noted, but overall
he's decided to keep this one.**

TABLE OF CONTENTS

CHAPTER

1	Brain SPECT Imaging: An Introduction	5
2	Images, Normal and Abnormal <i>How SPECT is interpreted and rated</i>	10
3	Images of Functional Neuroanatomy	13
4	Images of Strokes <i>Compelling Reasons Not to Smoke</i>	20
5	Images of Dementia versus Pseudodementia	24
6	Images of Brain Trauma <i>Wear a helmet, Avoid fights, No headers in soccer, Wear your seatbelt, Play golf instead of football</i>	28
7	Images of Depression	39
8	Images of Bipolar Disorder and Schizophrenia	45
9	Images of the Ring of Fire <i>Angry, Moody, and Oppositional</i>	50
10	Images of PMS <i>Is it real? You bet!</i>	56
11	Images of Anxiety	67
12	Images of Attention Deficit Disorder	71
13	Images of Obsessive Compulsive Spectrum Disorders	79
14	Images of Violence	85
15	Images of Alcohol and Drug Abuse <i>Brain Pollution and the Real Reason You Shouldn't Use</i>	94
16	Images of Treatment <i>Hope for Healing</i>	105

Section 1

BRAIN SPECT IMAGING *An Introduction*

On November 8, 1895 in Wurzburg Germany, Wilhelm Roentgen, a physicist at the University of Wurzburg, was working late in his laboratory. In an experiment he had been conducting before dinner, he had been sending an electric current through a tube. Without warning, a crystalline material on the other side of the room started emitting light. This made no sense to him. The rays produced by the tube could only travel a few centimeters; there was no way that they could travel all the way across the room to the crystal. Where was the light from the crystal coming from? When Roentgen came back after dinner, he tried the experiment again. This time he blackened the room, blocking out all light from the windows and covering the tube with black cardboard so no light could possibly escape when he sent another electric current through it. Yet still the crystalline material on the other side of the lab emitted visible light. Roentgen realized that it was caused by some kind of rays coming from the tube that were far more penetrating than he thought. Since he had never seen this phenomenon reported in the literature before and didn't know what the emitted rays were, he named them X-rays to signify their unknown nature.

Roentgen invited his wife Bertha into his lab to witness the experiment. The week before Christmas he made an X-ray of the bones in her left hand -- the first X-ray ever of the human body.

After Roentgen published a short paper on the phenomenon, the newspapers sensationalized his discovery. The physicist's life was never the same again. In 1901 he won the first Nobel Prize in physics. An intensely private man, he did not relish the attention he got for his discovery. He certainly could not predict the impact his discovery would have on the lives of many millions of people.

Many remarkable inventions and discoveries came out of the second half of the 19th century in science, but it would be hard to overestimate the sensation Roentgen created with his skeletal photographs and the impact of his discovery on medicine, for it provided a way to see into the body without cutting it open. It was to be many years before scientists understood the true nature of X-rays. Roentgen did not, at the time, realize that what he had done was to cause the crystal in his laboratory to emit visible radiation, when it was struck by X-rays from the vacuum tube. By bombarding the atoms of the crystal with the high energy photons from the X-rays, he had knocked the electrons of the crystal's atoms out of orbit. Whenever electrons move back from a higher energy

orbit into a lower energy orbit they emit photons. This process is called electromagnetic radiation. Depending on where the emission is on the electromagnetic spectrum, it will be visible or not visible to the naked eye. In Roentgen's case, the electromagnetic rays were clearly visible.

Roentgen's first paper on the subject described about 40 different properties of his newly discovered X-rays. In 1896, when another scientist, Henri Becquerel, read Roentgen's paper he noticed that these properties had a number of similarities to those he himself had observed in an unusual rock in his possession. When he first observed the rock, he did not realize it was emitting its own energy. He accidentally exposed some photographic plates to his uranium rock and he noticed changes consistent with Roentgen's discovery. But where Roentgen had accidentally "created" radiation with his device, Becquerel was the first to discover the principal of naturally occurring radioactivity.

Marie Curie, one of Becquerel's students, found that certain samples of uranium had higher levels of activity than other samples. Upon investigation she discovered the reason: other elements, polonium (which gives off 700 times more radiation than uranium) and radium (which gives off a million more times more radiation than uranium) were mixed in with the uranium ore. Radium and polonium were important in that they alerted scientists to the fact that there were particles in nature that produced their own energy, as opposed to everything else on Earth, which require energy from an outside source -- the sun. For the next 40 years, other naturally occurring radioactive elements were discovered.

Radium was the first radioactive material ever used in medicine. However, it has an extremely long half-life (time it takes an isotope to decay from a level of radioactivity down to half that level). Simply for the sake of science, no one was interested in injecting a long-lived radioactive isotope into the body that was going to remain destroying cells for years to come. Therefore, when the medical possibilities for radioactive substances as a detection agent were recognized, scientists realized they needed to find an isotope that would do the job without doing any significant damage.

In Marie Curie's day, however, they were stuck with whatever nature had made available, and the radioactive materials occurring naturally had a half-life that lasted many, many years. It was important to scientists to be able to use radioactive substances with properties that allowed them to be safe inside the human body. In other words, they needed isotopes that would assist in understanding function and then disappear. Irene Curie (Marie's daughter) recognized this and found a way to artificially create radioactive material. Eventually technetium, was discovered and proved to be a very good short-acting isotope. It is the isotope we use in our lab. Of course, they could not possibly have known how to produce mass quantities of radioisotopes at the turn of the century. It was not until World War II, after the Manhattan Project developed the atomic bomb, that

science was able to achieve that. The experimental nuclear reactor furnished a rich source of neutrons that generated radioisotopes in large quantities at a relatively low cost. From then on, there was no scarcity of radioactive material, for national defense or scientific research.

Many other important discoveries along the way helped nuclear medicine get where it is today. As early as 1903, Alexander Graham Bell suggested the first clinical use of radioactive material. In a letter he suggested that possibly radium in a sealed glass tube could be inserted near a tumor in a patient. One of the most important discoveries, however, was made in 1927 in Boston by Herman Blumgart and his colleagues who used a diluted solution of radon to study circulation. By measuring how fast the diluted Radon flowed from one side of the body to the other, they were able to measure circulation and cardiac functions. Consequently they were the first to use radioactive isotopes to measure physiological functions in the body, and their discovery ushered in the "age of nuclear medicine." The studies of Dr. Blumgart and others conducted in the 1920s in observing the transportation of radioactive elements in the body lead to the conclusion that radioactive material could be used as a tracer. The "age of nuclear medicine" has created new and safer ways to treat people suffering from disease and injury.

What Is SPECT?

What is SPECT? It is an acronym for Single Photon Emission Computerized Tomography. It is a sophisticated nuclear medicine study that looks directly at cerebral blood flow and indirectly at brain activity (or metabolism). In this study, a radioactive isotope (which, as we will see, is akin to a myriad of beacons of energy or light) is bound to a substance that is readily taken up by the cells in the brain.

A small amount of this compound is injected into the patient's vein where it runs throughout the blood stream and is taken up by certain receptor sites in the brain. The patient then lies on a table for 14-16 minutes while a SPECT "gamma" camera rotates slowly around his head. The camera has special crystals that detect where the compound (signaled by the radioisotope acting like a beacon of light) has gone. A supercomputer then reconstructs 3-D images of brain activity levels. The elegant brain snapshots that result offer a sophisticated blood flow/ metabolism brain map. With these maps, physicians have been able to identify certain patterns of brain activity that correlate with psychiatric and neurological illnesses.

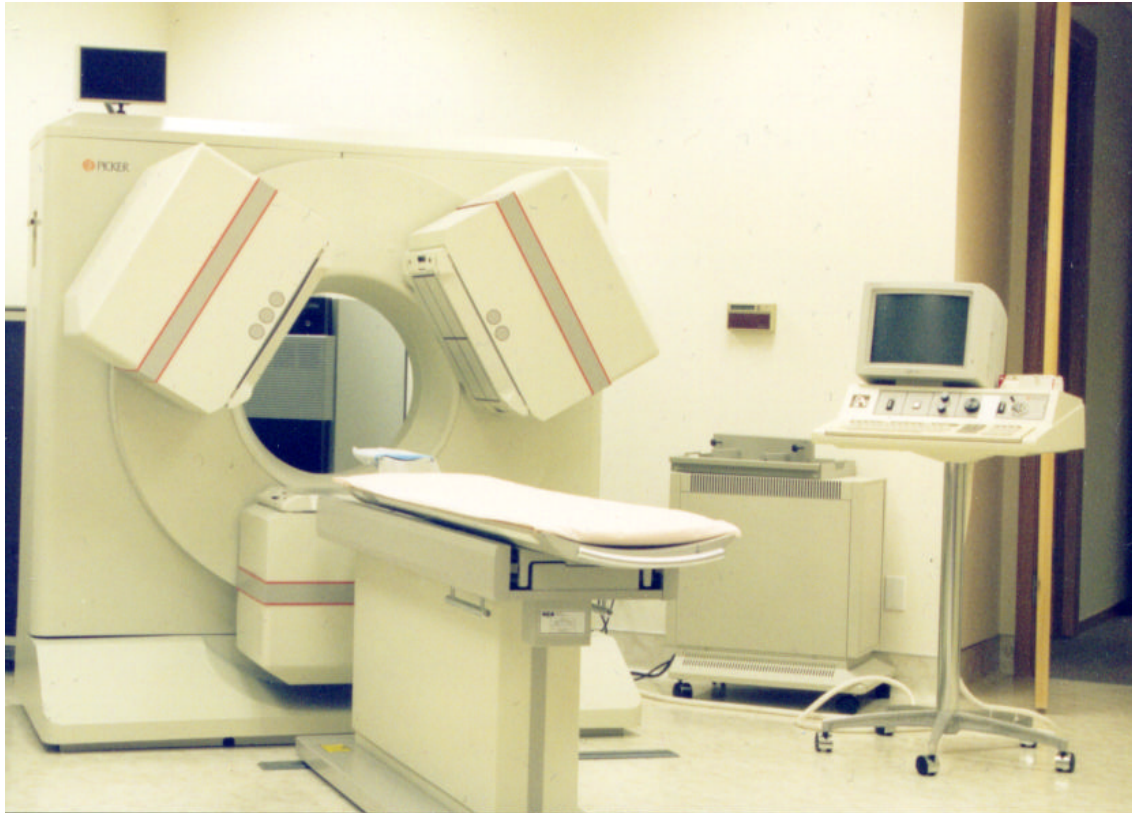SPECT studies belong to a branch of medicine called nuclear medicine. Nuclear (refers to the nucleus of an unstable or radioactive atom) medicine uses radioactively tagged compounds (radiopharmaceuticals), because the unstable atoms emit gamma rays

when they decay acting like a beacon of energy or light from each location where they go. An unstable atom is always looking for stability, and it will keep changing or degrading, until it reaches its most stable form. At each step of decay, it emits a gamma ray (portion of energy). Scientists can detect those gamma rays with film or special crystals and can record an accumulation of the number of beacons that have decayed in each area of the brain. These unstable atoms are essentially tracking devices – they track which cells were most active and had the most blood flow and those cells which are least active and have the least blood flow.

Nuclear medicine studies measure the physiological functioning of the body, and they can be used to diagnose a multitude of medical conditions: heart disease, certain forms of infection, the spread of cancer, and bone and thyroid disease. My own area of expertise in nuclear medicine, the brain, uses SPECT studies to help in the diagnosis of head trauma, dementia, atypical or unresponsive mood disorders, strokes, seizures, the impact of drug abuse on brain function and atypical or unresponsive aggressive behavior.

During the late 70s and 80s SPECT studies were being replaced in many cases by the sophisticated anatomical CAT and later MRI studies. The resolution of those studies was far superior to SPECT as far as seeing tumors, cysts and blood clots. In fact, they nearly eliminated the use of SPECT studies altogether. Yet despite their clarity, CAT scans and MRIs could offer only images of a static brain, and its anatomy; they gave little or no information on the activity in a working brain. It was analogous to looking at the parts of a car's engine without being able to turn it on. In the last decade it has become increasingly recognized that many neurological and psychiatric disorders are not disorders of the brain's anatomy, but problems in how it functions.

Two technological advancements have encouraged the use, once again, of SPECT studies. Initially, the SPECT cameras were single-headed, and they took a long time to scan a person's brain (up to an hour). People had trouble holding still that long, and the images were fuzzy, hard to read (earning nuclear medicine the nickname "unclear medicine") and they did not give much information about the functioning deep within the brain. Then multi-headed cameras were developed which were able to image the brain much faster and with enhanced resolution. The advancement of computer technology also allowed for improved data acquisition from the multi-headed systems. The brain SPECT studies of today, with their higher resolution, can see into the deeper areas of the brain with far greater clarity and show what CAT scans and MRIs cannot – how the brain actually functions.



Picker Prism Triple Headed 3,000 Gamma Camera

Section 2

NORMAL IMAGES

How SPECT Is Interpreted

SPECT studies can be displayed in a variety of different ways. Traditionally, the brain is examined in three different planes: horizontally (cut from top to bottom), coronally (cut from front to back), and sagittally (cut from side to side) – see below for examples of each of these planes. What do physicians see when they look at a SPECT study? We examine it for symmetry and activity levels indicated by shades of color (in different color scales selected depending on the physician's preference, including gray scales) and compare it to what we know a normal brain looks like. A normal SPECT image reveals homogeneous and uniform tracer accumulation throughout the cerebral cortex, with the cerebellum being the area with the most intense activity. Chiron studied the normal progression of cerebral perfusion in children and found that by the age of 2 or 3 there is the same relative perfusion patterns as those seen in adults.

The images that accompany this atlas will be mostly two kinds of three dimensional (3D) images of the brain.

One kind is a *3D surface image*, looking at the blood flow of the brain's cortical surface. These images are helpful for picking up cortical surface areas of good activity as well as underactive areas. They are helpful to look at strokes, brain trauma, the effects from drug abuse, etc. A normal 3D surface scan shows good, full, symmetrical activity across the brain's cortical surface.

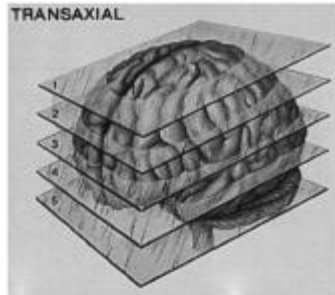
The other kind is a *3D active brain image* comparing average brain activity to the hottest 15% of activity. These images are helpful for picking up areas of overactivity, as seen in active seizures, obsessive compulsive disorder, anxiety problems, certain forms of depression, etc. A normal 3D active scan shows increased activity (seen by the light color) in the back of the brain (the cerebellum and visual or occipital cortex) and average activity everywhere else (shown by the background grid).

Physicians are usually alerted that something is wrong in one of three ways: (a) they see too much activity in a certain area; (b) they see too little activity in a certain area; or (c) they see asymmetrical areas of activity, which ought to be symmetrical.

VIEWING BRAIN SPECT STUDIES

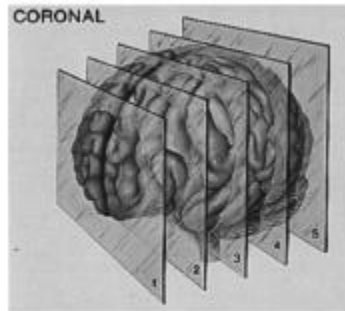
HORIZONTAL VIEW (transaxial)

The brain is viewed in horizontal slices, cut from top to bottom.
It is as if you are looking down from a bird's eye view.



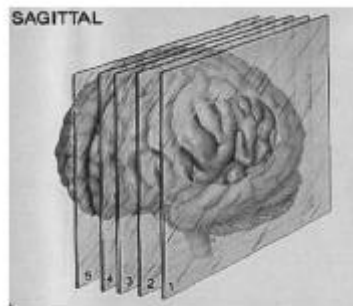
CORONAL VIEW (front on view)

The brain is viewed in vertical slices, cut from front to back.
It is as if you are looking face on or front on to the brain.

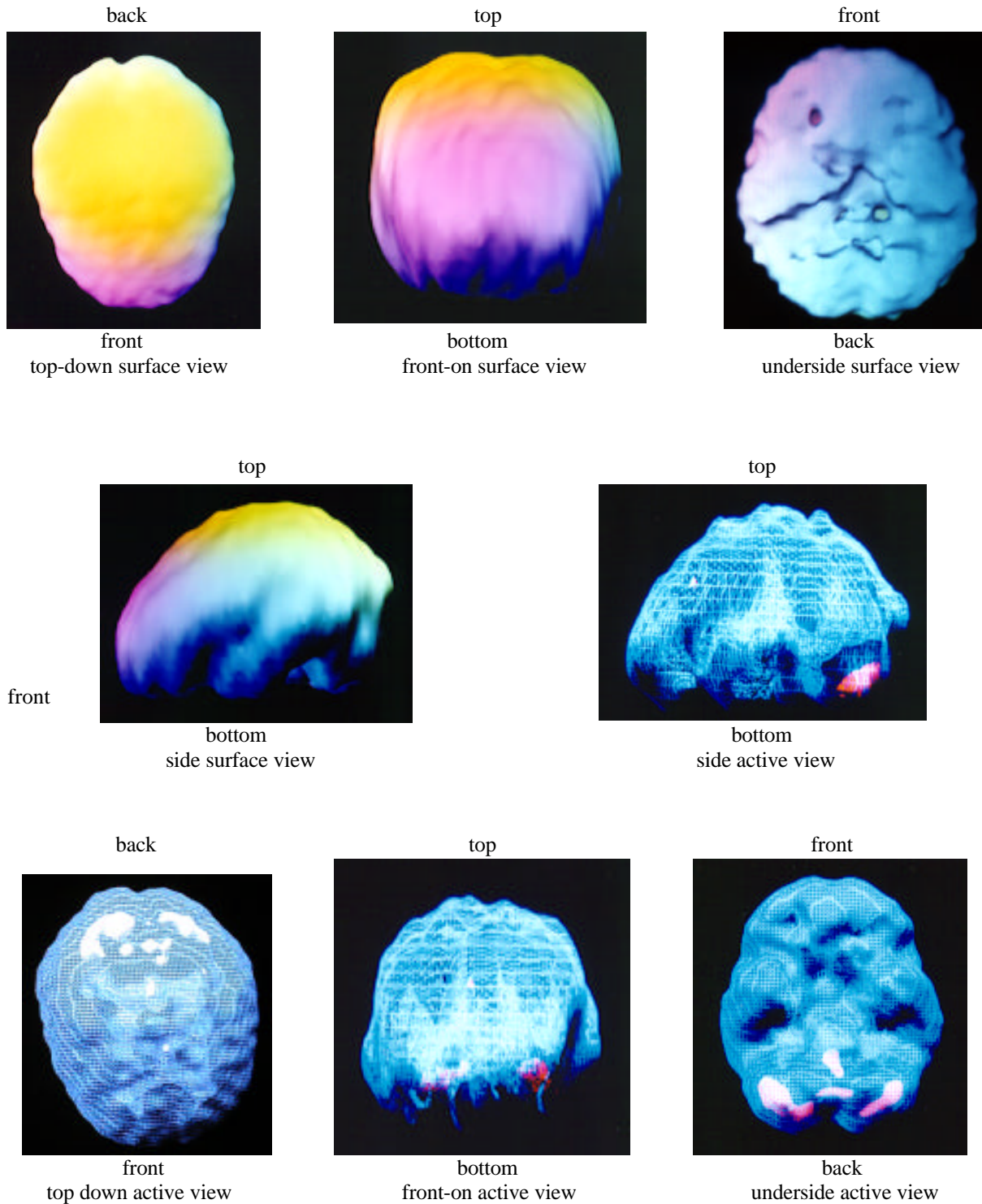


SAGITTAL VIEW (side to side)

The brain is viewed in vertical slices, cut from side to side.
It is as if you are looking at the brain from the side.



Normal 3D Brain SPECT Studies

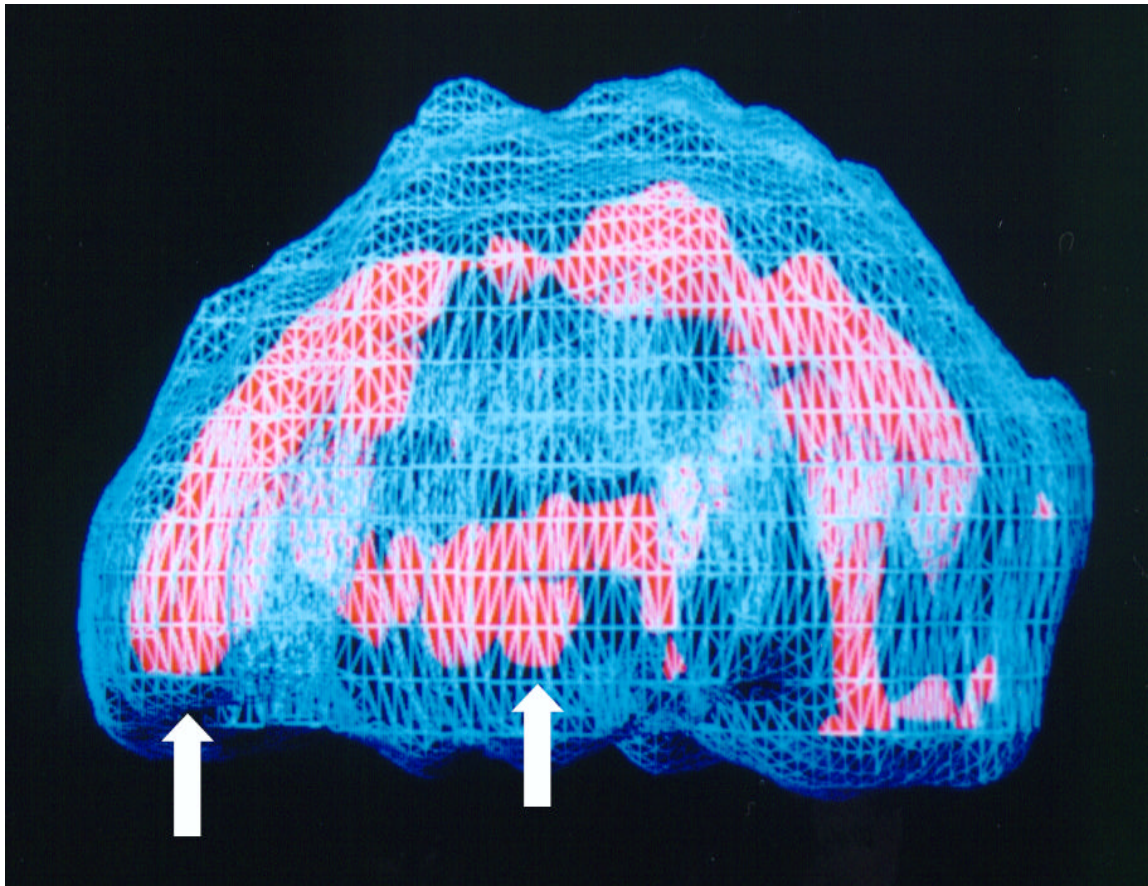


The surface images (1-4) are rendered by looking at the most active 45% of brain activity. The active images are rendered by comparing the most active 45% or average brain activity (blue color) to the most active 15% (red or white color), the back of the brain is normally the most active part of the brain.

Section 3

FUNCTIONAL NEUROANATOMY

In order to best understand this atlas it is important to have a sense of the functional neuroanatomy of the brain. Over the next several pages there is a brief summary of the 5 major brain systems that relate to behavior, along with the general location seen on SPECT of these areas.

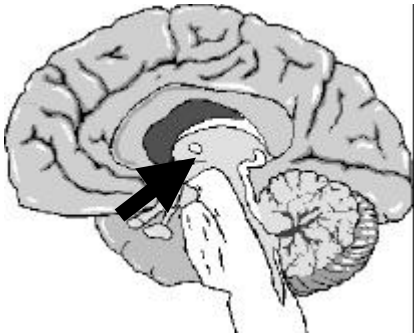


left side active view

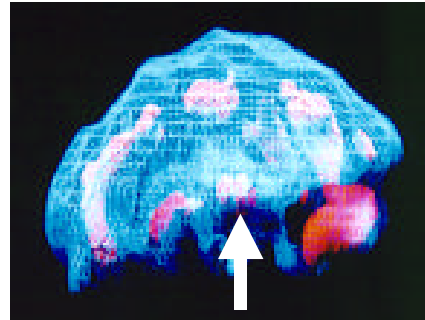
anterior cingulate
(front arrow)

deep left temporal lobe
(back arrow)

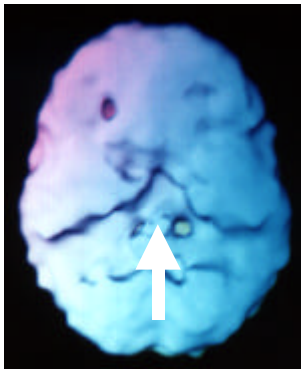
The Deep Limbic System



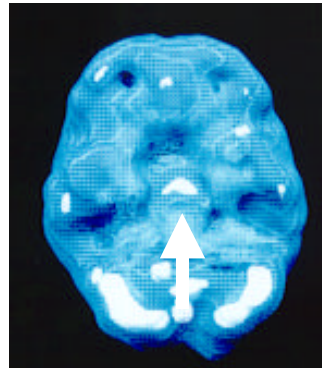
side view



side active view



underside surface view



underside active view

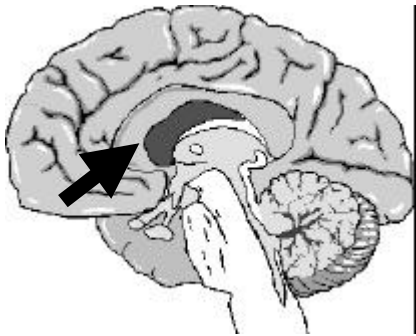
Functions

- sets the emotional tone of the mind
- filters external events through internal states (emotional coloring)
- tags events as internally important
- stores highly charged emotional memories
- modulates motivation
- controls appetite and sleep cycles
- promotes bonding
- directly processes the sense of smell
- modulates libido

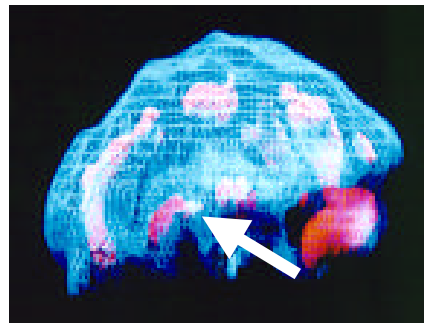
Problems

- moodiness, irritability, clinical depression
- increased negative thinking
- perceive events in a negative way
- decreased motivation
- flood of negative emotions
- appetite and sleep problems
- decreased or increased sexual responsiveness
- social isolation

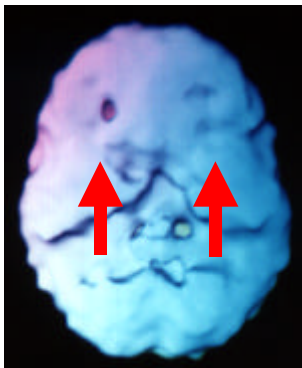
The Basal Ganglia System



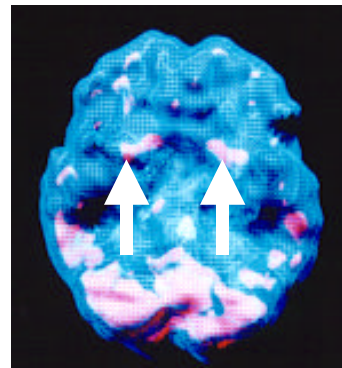
side view



left side active view



underside surface view



underside active view

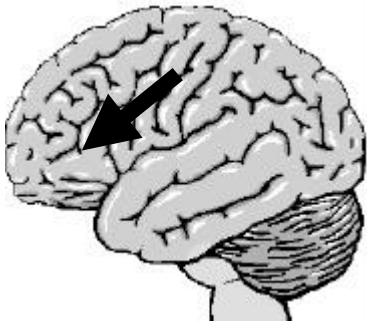
Functions

- integrates feeling and movement
- shifts and smoothes fine motor behavior
- suppression of unwanted motor behaviors
- sets the body's idle or anxiety level
- enhances motivation
- pleasure/ecstasy

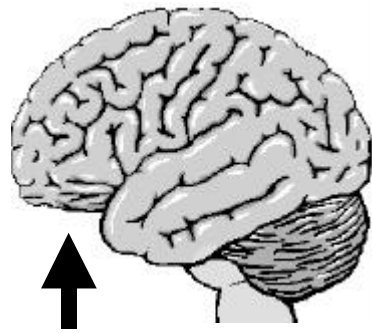
Problems

- anxiety, nervousness
- panic attacks
- physical sensations of anxiety
- tendency to predict the worst
- conflict avoidance
- Gilles de la Tourette's Syndrome/tics
- muscle tension, soreness
- tremors
- fine motor problems
- headaches
- low or excessive motivation

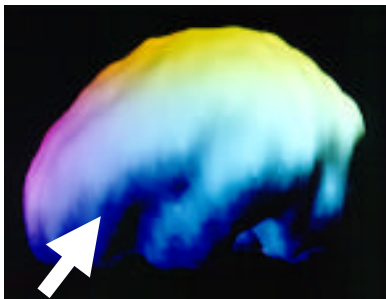
The Prefrontal Cortex



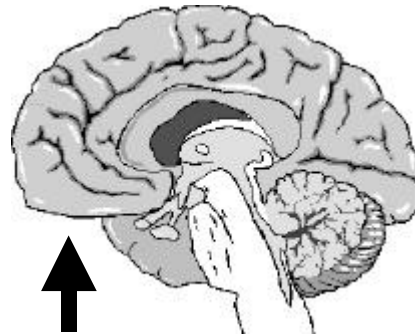
dorsal lateral prefrontal cortex
outside view



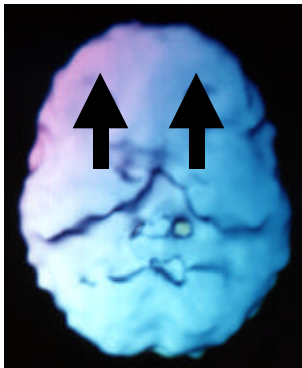
inferior orbital prefrontal cortex
outside view



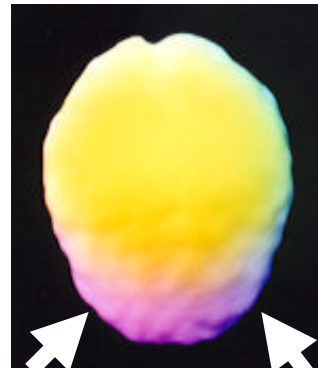
side surface view
dorsal lateral prefrontal area



inferior orbital prefrontal area
inside view



underside surface view
inferior orbital prefrontal area



top-down surface view
dorsal lateral prefrontal area

Prefrontal Cortex

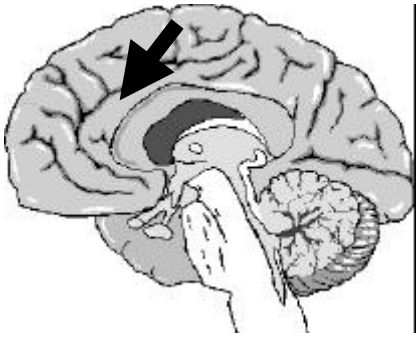
Functions

- attention span
- perseverance
- judgment
- impulse control
- organization
- self-monitoring and supervision
- problem solving
- critical thinking
- forward thinking
- learning from experience
- ability to feel and express emotions
- influences the limbic system
- empathy

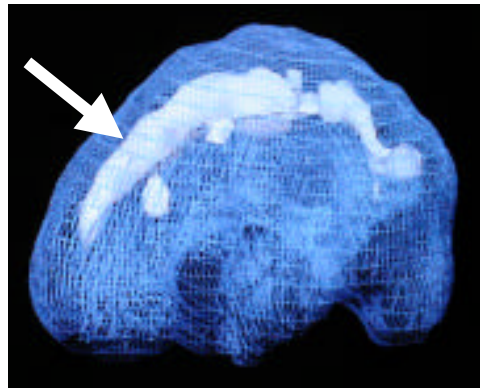
Problems

- short attention span
- distractibility
- lack of perseverance
- impulse control problems
- hyperactivity
- chronic lateness, poor time management
- disorganization
- procrastination
- unavailability of emotions
- misperceptions
- poor judgement
- trouble learning from experience
- short term memory problems
- social and test anxiety

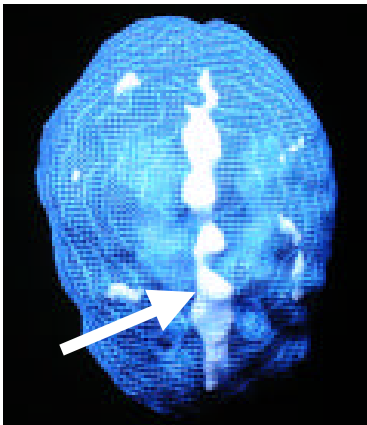
The Cingulate Gyrus



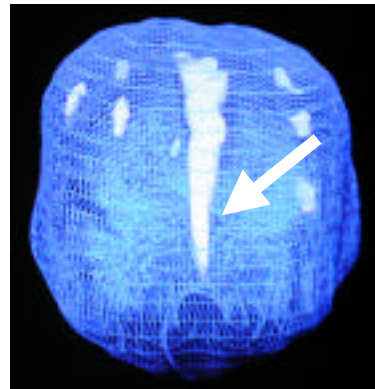
inside side view



side active view



active top-down view



active front-on view

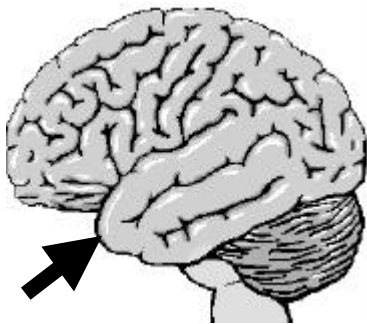
Functions

- allows shifting of attention
- cognitive flexibility
- adaptability
- helps the mind move from idea to idea
- gives the ability to see options
- helps you go with the flow
- cooperation

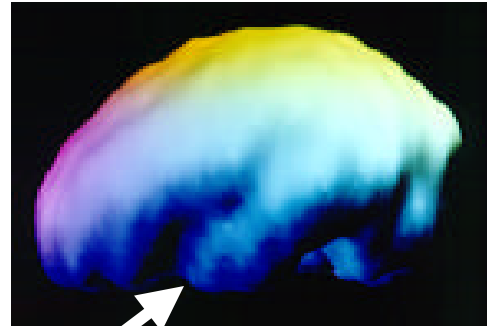
Problems

- worrying
- holds onto hurts from the past
- stuck on thoughts (obsessions)
- stuck on behaviors (compulsions)
- oppositional behavior, argumentative
- uncooperative, tendency to say no
- addictive behaviors (alcohol or drug abuse, eating disorders, chronic pain)
- cognitive inflexibility
- obsessive compulsive disorder
- OCD spectrum disorders
- eating disorders, road rage

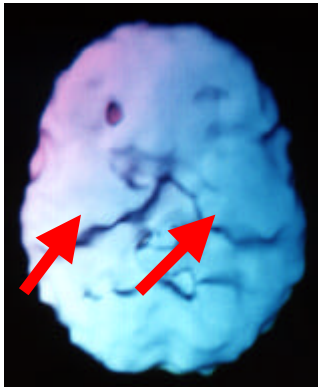
The Temporal Lobes



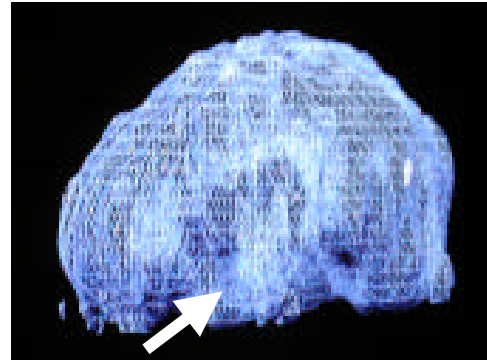
side view



side surface view



underside surface view



active side view

Functions

Dominant Side (usually the left)

- understanding and processing language
- intermediate term memory
- long term memory
- auditory learning
- retrieval of words
- complex memories
- visual and auditory processing
- emotional stability

Non-dominant Side (usually the right)

- recognizing facial expression
- decoding vocal intonation
- rhythm
- music
- visual learning

Problems

Dominant Temporal Lobe

- aggression, internally or externally driven
- dark or violent thoughts
- sensitivity to slights, mild paranoia
- word finding problems
- auditory processing problems
- reading difficulties
- emotional instability

Non-dominant Temporal Lobe

- difficulty recognizing facial expression
- difficulty decoding vocal intonation
- implicated in social skill struggles

Either/Both Temporal Lobe Problems

- memory problems, amnesia
- headaches or abdominal pain without a clear explanation
- anxiety or fear for no particular reason
- abnormal sensory perceptions, visual or auditory distortions
- feelings of déjà vu or jamais vu
- periods of spaciness or confusion
- religious or moral preoccupation
- hypergraphia, excessive writing
- seizures

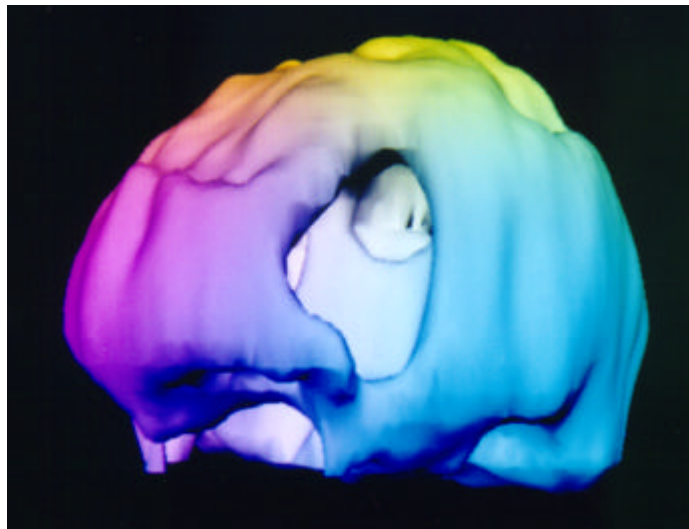
Section 4

IMAGES OF STROKES

Compelling Reasons Not To Smoke!

Strokes are one of the leading causes of death in the U.S. They are caused by either a blood clot that chokes off blood supply to an area of the brain or by a blood vessel breaking. Cigarette smoking is one of the most significant risk factors for strokes. On SPECT, strokes are demonstrated by areas of significant decreased or absent activity. SPECT is often helpful in the evaluation and management of cerebral vascular disease. After an acute stroke' early SPECT depicts the area of ischemia with greater accuracy than either computed tomography or magnetic resonance imaging. When the perfusion defect is large' the likelihood of hemorrhagic complications or herniation increases. Reperfusion of an arterial territory after thrombolysis can be documented more conveniently with SPECT than with angiography. SPECT before and after the injection of acetazolamide has been used to assess the vascular reserve in patients with severe stenosis of the proximal vessels of the cerebrovascular tree. Here are several examples.

Left Frontal Stroke

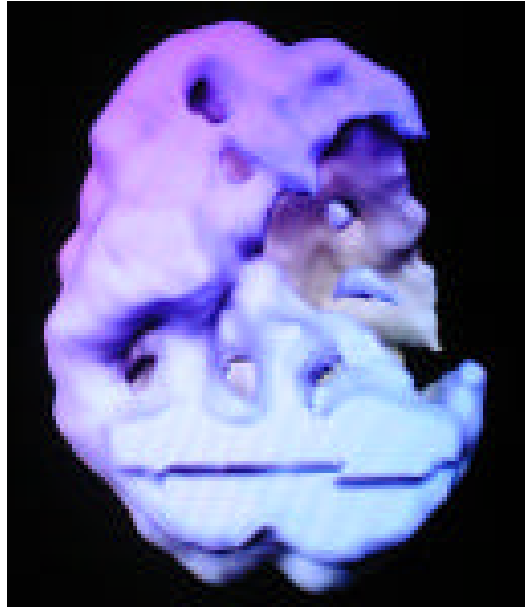

left side oblique surface view

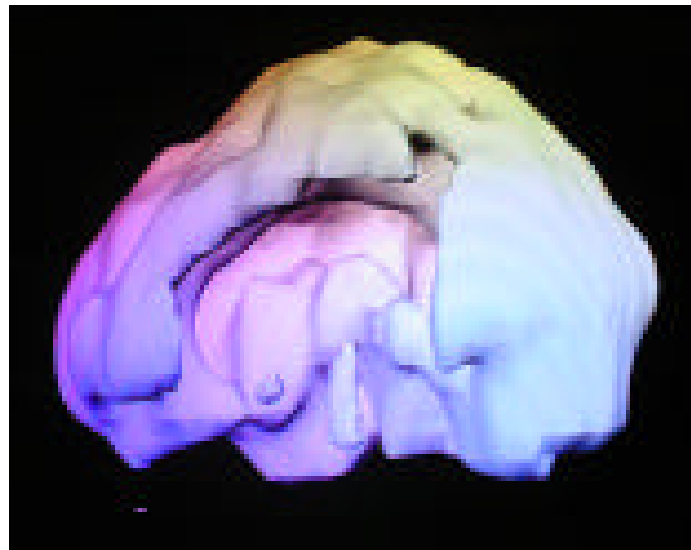
Ellen, 63, was suddenly paralyzed on the right side of her body. Unable to even speak, she was in a panic and her family was extremely concerned. As drastic as these symptoms were, two hours after the event, her CAT scan was still normal. Suspecting a stroke, the emergency room physician ordered a brain SPECT study that showed a hole of activity in her left frontal lobe caused by a clot that had choked off the blood supply to this

part of the brain. From this information, it was clear that a stroke had occurred and her doctors were able to take measures to limit the extent of the damage. Ellen was a smoker.

Left Frontal Stroke



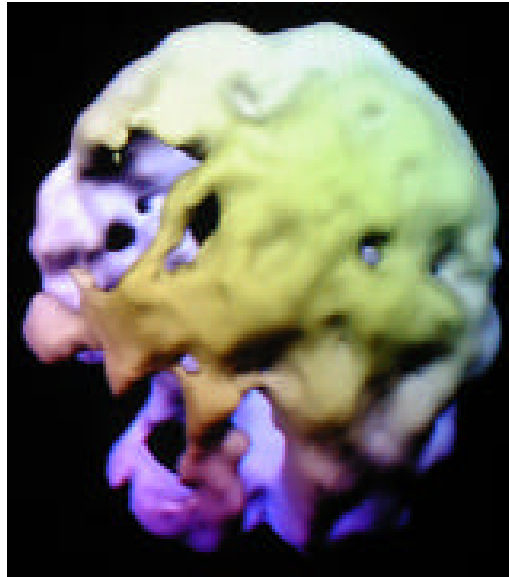
underside surface view



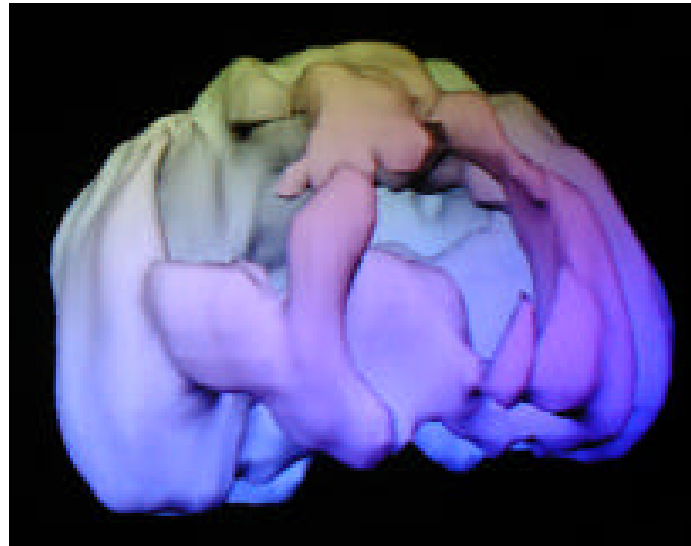
left side surface view

Bill, 48 year old male with left frontal lobe stroke, affecting speech, mood and temperament. Although Bill was not a cigarette smoker, he had over 10 years of moderate marijuana smoking.

Two Right Sided Strokes



top down surface view



right side surface view

Nancy was a 59-year-old woman suffering from severe depression that had been nonresponsive to treatment. Upon admission to a psychiatric hospital a SPECT study was done to evaluate her condition. Since she had not experienced any symptoms that would point to this, I was surprised to see that she had had two large strokes. Nearly immediately her non-responsive depression had made more sense to me. Sixty percent of the people who have frontal lobe strokes experience severe depression within a year. As a result of the SPECT study, I sought immediate consultation with a neurologist who evaluated her for the possible causes of the stroke, such as plaques in the arteries of the neck or abnormal heart rhythms. He felt the stroke had come from a blood clot and placed her on blood thinning medication to prevent further strokes. Nancy was a smoker.

Section 5

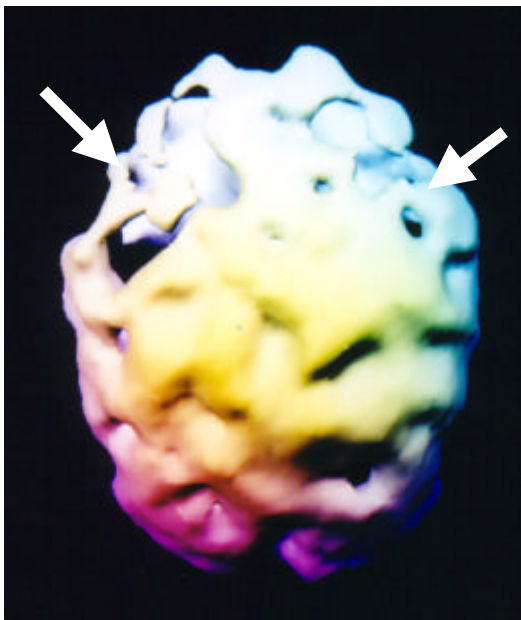
IMAGES OF DEMENTIA VS PSUEDODEMENTIA

As the population ages, the incidence of dementia in the U.S. will become an even more common problem and take up an even larger percentage of the health care budget. With the advent of new medications that slow the course of some dementing processes, diagnostic tools that help in the early differential diagnosis of dementia is essential. The SPECT pattern for Alzheimer's Disease is typically bilateral hypoperfusion in the parietal and temporal regions of the brain with frontal lobe hypoperfusion occurring later in the illness. Multi-infarct dementia is characterized by multiple areas of decreased perfusion. HIV dementia is typically seen by decreased patchy uptake across the cortex. Frontal lobe dementias (as the name indicates) are often characterized by very poor frontal lobe perfusion. Pseudodementia (another condition, such as depression, that clinically appears like dementia) will not have a typical dementia pattern and may be more like a depression pattern.

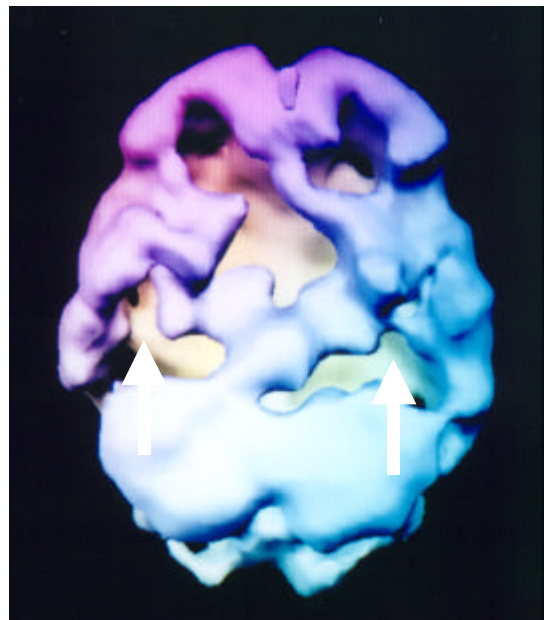
Here are several examples of how SPECT can be useful in the evaluation and treatment of dementia-like presentations.

Alzheimer's Disease

bilateral decreased parietal and temporal lobe activity



top-down surface view



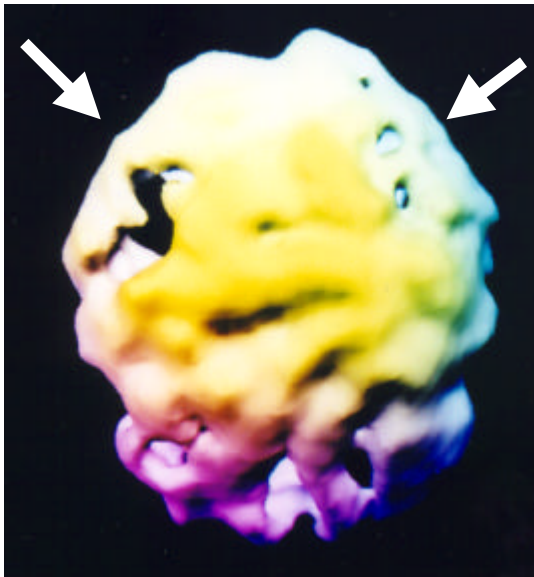
underside surface view

When Frank, a wealthy, well-educated man, entered his seventies, he began to grow forgetful. At first it was over small things, but as time went on the lapses of memory progressed to the point where he often forgot essential facts of his life: where he lived, his wife's name and even his own name. His wife and children, not understanding the change in behavior, were aggravated with his absent-mindedness and often angry at him for it. Frank's SPECT study showed a marked suppression across the entire brain, but especially in the frontal lobes, the parietal lobes and temporal lobes. This was a classic Alzheimer's disease pattern. By showing the family these images and pointing out the physiological cause of Frank's forgetfulness, in living images, I helped them understand that he was not trying to be annoying, but had a serious medical problem.

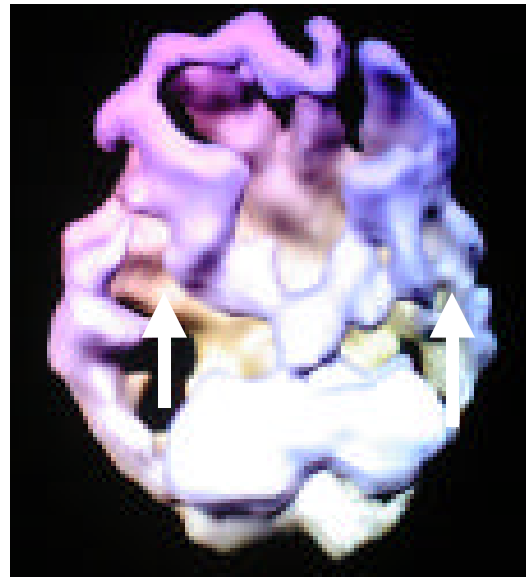
Consequently, instead of blaming him for his memory lapses, they began to show compassion towards him, and they developed strategies to deal more effectively with the problems of living with a person who has Alzheimer's Disease. In addition, I placed Frank on new experimental treatments for Alzheimer's Disease that seemed to slow the progression of the illness.

Alzheimer's Disease

Here is a scan of a 92 year old man with Alzheimer's Disease who had become forgetful, frequently lost away from home, forgot how to do simple things such as dress himself and began getting aggressive with his wife. Notice the extensive frontal lobe involvement.



top-down surface view

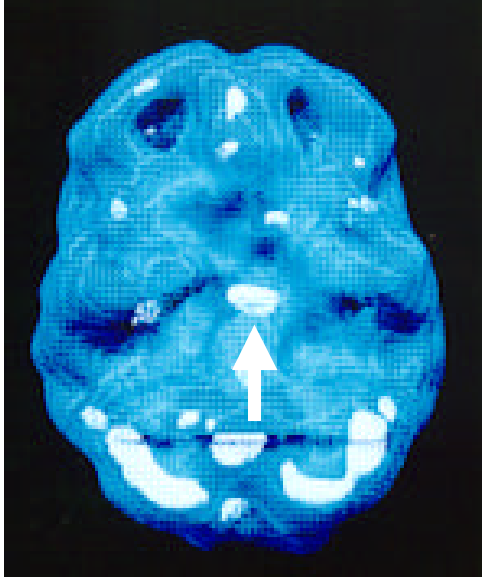


underside surface view

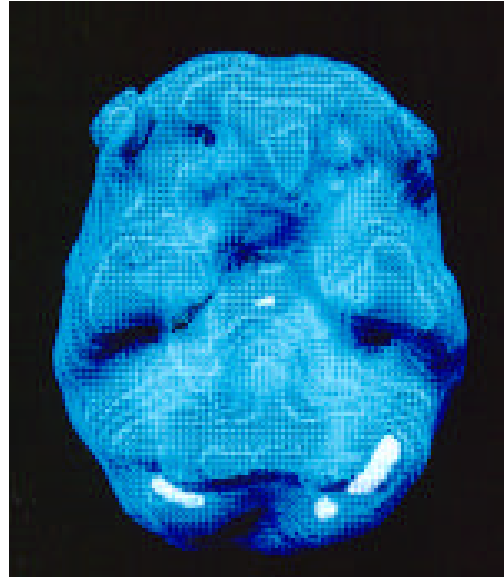
notice marked overall suppression, especially in the parietal lobes (arrows left images) and temporal lobes (arrows right image)

Pseudodementia

good temporal and parietal lobe perfusion, with increased limbic and/or decreased prefrontal cortex activity



*underside active view
before treatment*



*underside active view
after treatment*

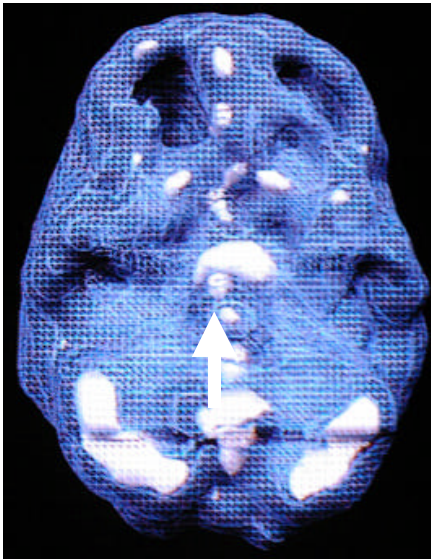
Before treatment notice good overall activity, with increased limbic system activity (center arrow), after treatment with Wellbutrin the limbic system normalizes.

I first met Margaret when she was 68 years old. Her appearance was ragged and unkempt. She lived alone and her family was worried because she appeared to have symptoms of serious dementia. They finally admitted her to the psychiatric hospital where I worked after she nearly burned the house down by leaving a stove burner on. When I consulted with the family I also found out that Margaret often forgot the names of her own children and frequently got lost when driving her car. Her driving habits deteriorated to the point where the Department of Motor Vehicles (DMV) had to take away her license after four minor accidents in a six month period. At the time when Margaret's family saw me, some members had had enough and were ready to put her into a supervised living situation. Some family members, however, were against the idea and wanted her hospitalized for further evaluation.

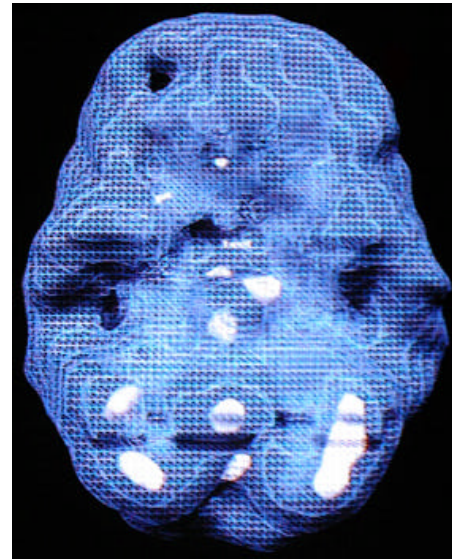
While at first glance it may have appeared that Margaret was suffering from Alzheimer's Disease, the results of her SPECT study showed full activity in her frontal, parietal and temporal lobes. If she had Alzheimer's Disease, there should have been evidence of decreased blood flow in those areas. Instead, the only abnormal activity shown on Margaret's SPECT was in the limbic system at the center of the brain where the activity was increased. Often, this is a finding in people suffering from depression. Sometimes in the elderly it can be difficult to distinguish between Alzheimer's Disease and

depression because the symptoms can be similar. Yet with pseudodementia (depression masquerading as dementia), a person may appear demented, yet not be at all. This is an important distinction to make because a diagnosis of Alzheimer's Disease would lead to prescribing a set of coping strategies to the family and possibly new experimental medications, whereas a diagnosis of some form of depression would lead to prescribing an aggressive treatment of antidepressant medication for the patient along with psychotherapy.

Here is another example.



underside active view
before treatment



underside active view
after treatment

Before treatment notice poor prefrontal cortex activity and increased limbic system activity, after treatment with imipramine the limbic system normalizes and the prefrontal cortex improves significantly.

Section 6

IMAGES OF BRAIN TRAUMA

Wear a helmet, Avoid fights

No headers in soccer, Wear your seatbelt

Play golf instead of football

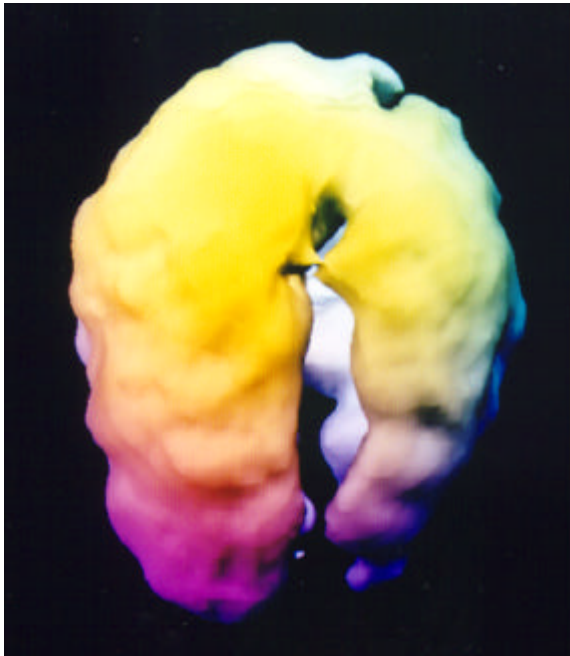
The impact of head trauma is often overlooked in psychiatry. Even minor head injuries to vulnerable parts of the brain can cause problems for years to come. SPECT is one of the best tools in evaluating functional deficits from head trauma that are often not seen by other studies, leading to more understanding and effective treatments for patients. Typically, SPECT findings in head trauma include focal areas of decreased activity, often in a contra-coup pattern (such as decreased activity in the left anterior prefrontal cortex and right occipital lobe or the anterior and posterior aspects of a temporal lobe) and, in some cases, marked hyperactivity over the site of the injury. In many cases we have seen increased “off center” cingulate gyrus activity after a head injury.

Documentation of head injuries is essential for several reasons. For school age children and teenagers it allows them to receive more specialized services. Knowledge of the injuries is often essential for legal/insurance reasons. Patient and family understanding of the effects of brain trauma enhances treatment compliance and a deeper understanding from family and support systems. Here are several examples.

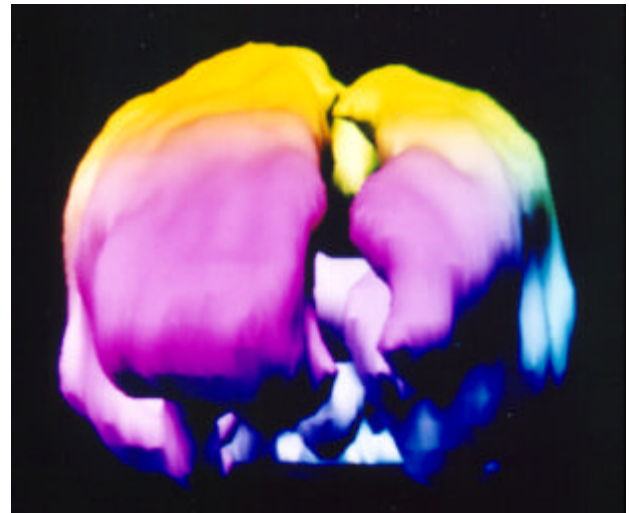
Tim, age 15, was a high school sophomore at a high school in Connecticut. From the time he was young he exhibited severe conduct problems. He had already been arrested for shoplifting, he frequently cut school and was defiant and abusive toward his parents. He did not get along with other teens at school and seemed to “never fit in.” He smoked a pack of cigarettes a day and frequently used both marijuana and cocaine. He had already been in one treatment program and was on his way to a second program when his parents brought him to our clinic. From an early age, Tim was hyperactive, impulsive, moody and frequently angry, especially whenever someone would tell him no. His temper flared quickly and often, often over minor or trivial incidences. He had tried numerous medications without success. His parents had heard about my clinic and decided to come across the country to see us.

His brain SPECT study showed severe damage to his left prefrontal cortex. It was one of the most severe cases I have ever seen. When he was 18 months old he fell down a flight of stairs. His mother said he was never quite the same since then. She could just tell there was a difference in his personality. Given the level of functional damage to Tim’s brain I decided to put him on a combination of an anticonvulsant medication and a stimulant. It helped lessen the

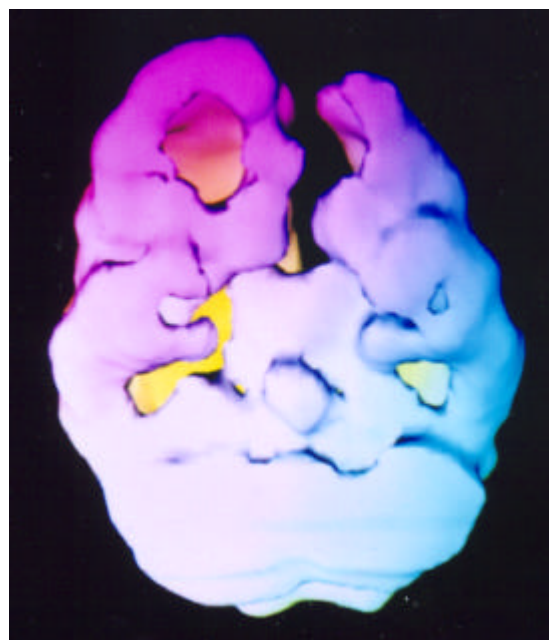
rage and improve his impulse control. Given the level of damage, his chances for having full executive function are not very promising. The goal of treatment is to utilize every prescription available to help Tim develop auxiliary internal supervision mechanisms. Otherwise, legal authorities will have to impose external supervision in some form of a contained setting, basically through no fault of Tim. He doesn't have the capacity for internal supervision that is housed in the prefrontal cortex.



top down surface view

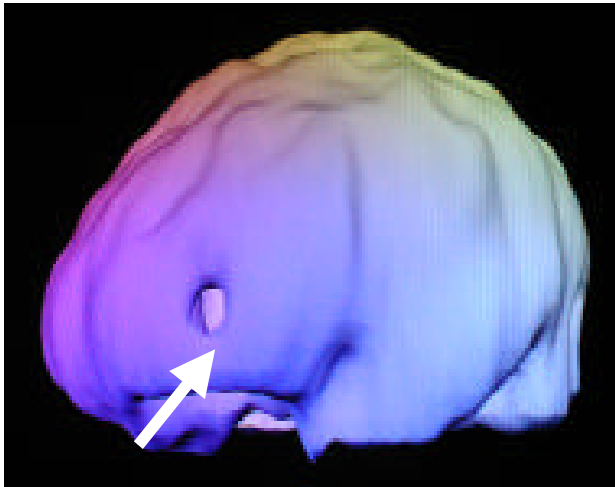

front on surface view



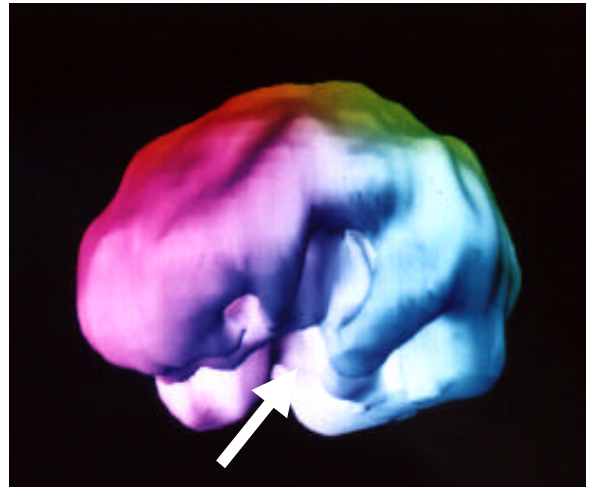underside surface view

note the marked decreased left prefrontal, left hemisphere and left occipital lobe



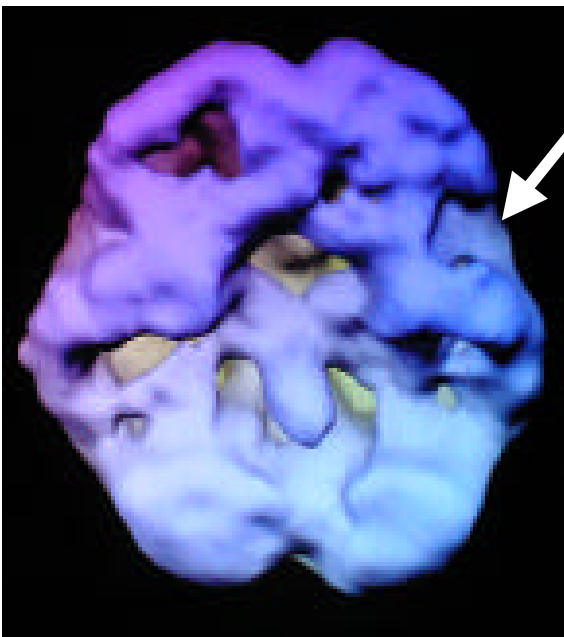
left side surface view

16 y/o head trauma at age 7
 school failure, substance abuse, impulsivity
 decreased left pfc



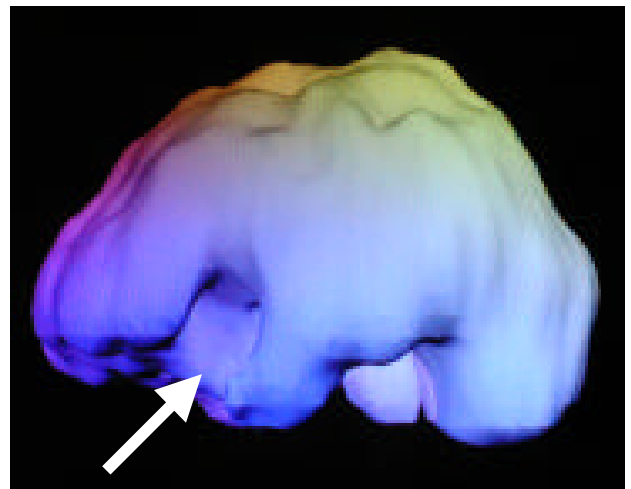left side surface view

79 y/o car ran into a pole age 20 y/o
 long history of aggression and irritability
 decreased left pfc and anterior temporal lobe

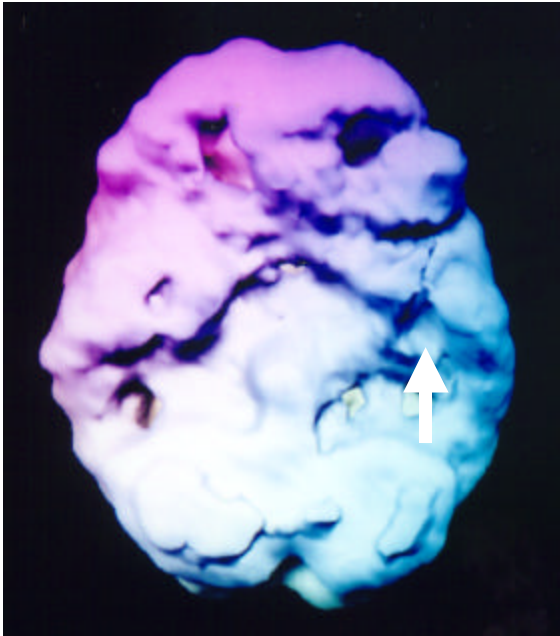


underside surface view

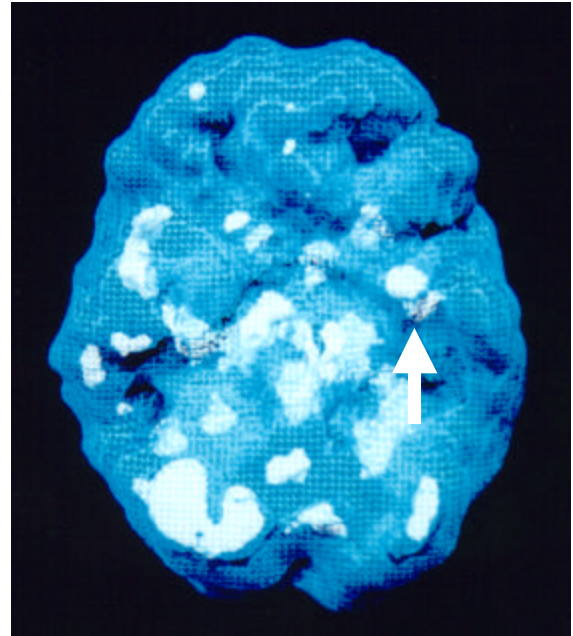
48 y/o male, football injury age 16, significant problems expressing feelings (alexithymia)
 decreased left pfc and anterior left temporal lobe



left side surface view

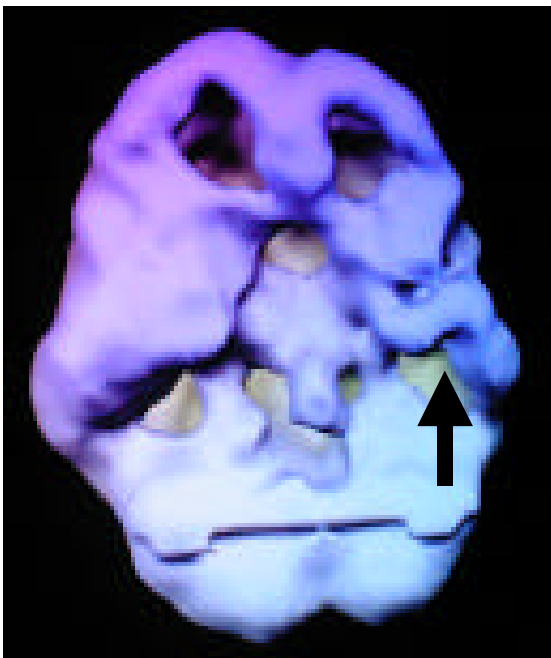


underside surface view

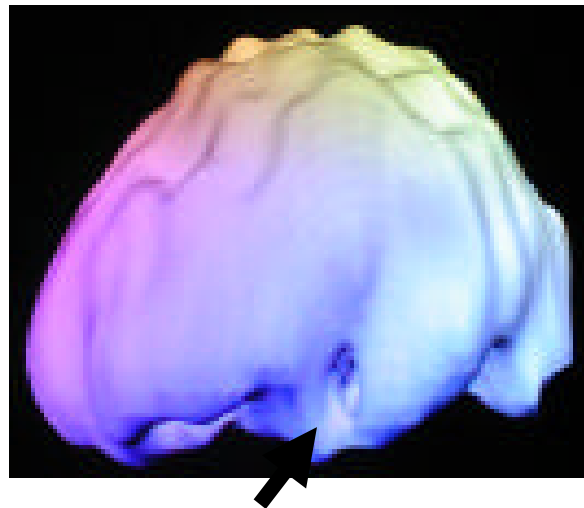

underside active view

56 y/o male, fell off porch into pile of bricks age 6 significant problems with temper, illusions and depression decreased left pfc and left temporal lobe (left image), increased deep left temporal lobe activity (right image)

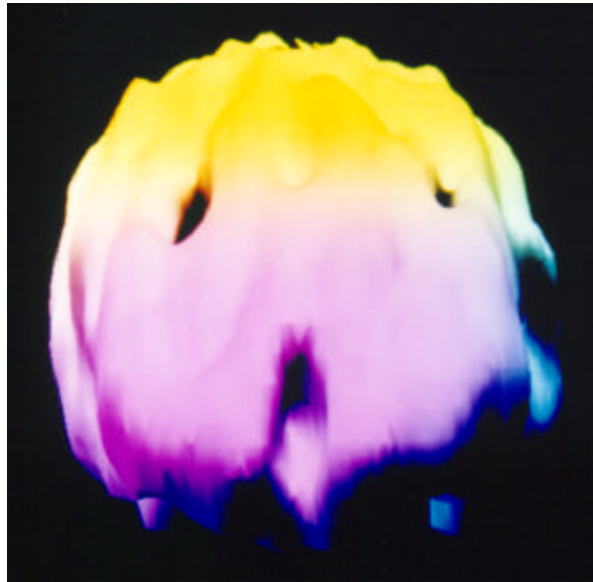

underside surface view



left side surface view

32 y/o female, rear ended by an 18 wheel semi-truck on the freeway, significant problems with irritability, depression and memory, decreased pfc and left temporal lobe (left image), decreased left anterior temporal lobe activity (right image)



*front on surface view
notice the dented area in the right anterior frontal pole*

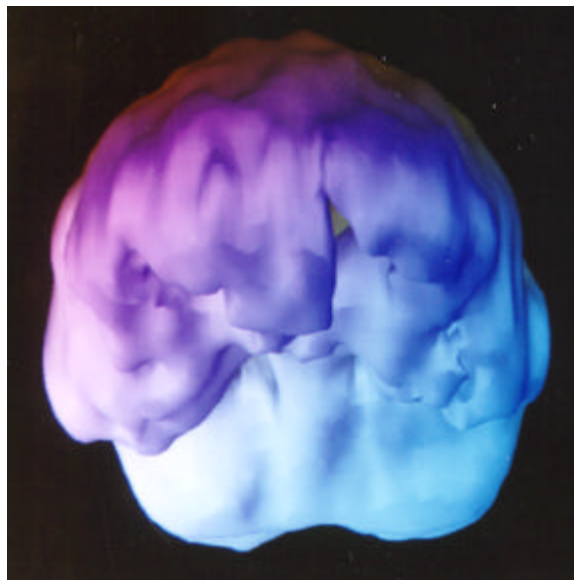
Betty was the most beautiful 88-year-old woman I had ever met. She was very proper and very proud. When she was a young woman she had emigrated from England after marrying a U.S. soldier. It was not her 90-year-old husband who brought her to the hospital to see me, however, it was her sister. Her husband, far from being supportive, angrily denied that his wife was suffering from serious cognitive problems. Yet during the evaluation process it was clear that Betty had severe memory problems; she did not know where she lived, her phone number, or her husband's name. I ordered a SPECT study that showed a dent in the right side of Betty's frontal lobe. It was obvious to me that she had, at some point in her life, suffered a significant head injury. When I asked her about it, all she could do was look down and cry; she could not give me details of the event. When I asked her sister, she reported that Betty and her husband had a stormy relationship and that he was abusive towards her. Sometimes he would grab her by the hair and slam her head into the wall. The sister wanted Betty to go to the police, but Betty said it would only make things worse.

Shortly after Betty was hospitalized, her husband began pressuring me to send her home. He kept protesting that there was nothing wrong with her, yet I knew that Betty needed to be removed from that environment so I contacted the Adult Protective Services. At Betty's hearing, I used her SPECT studies to convince the judge that her home held potential danger. He then ordered her to have a conservator, and she went to live with her sister.

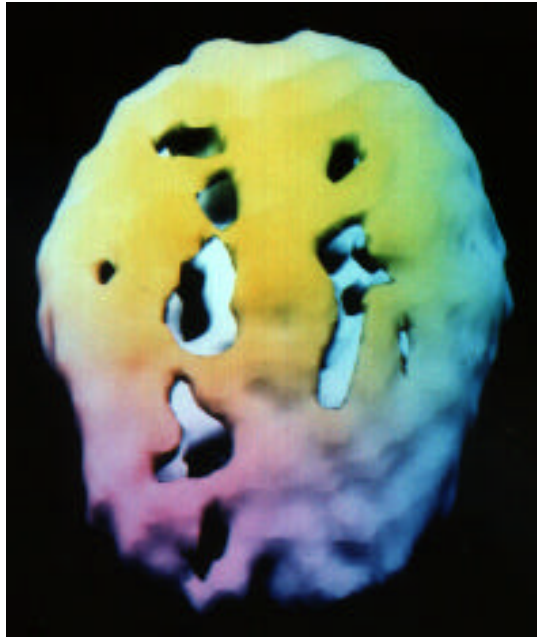
Here is another example. Zachary, age 10, was a fun loving, active boy who was loving, sweet and liked to please. He did well in kindergarten and was liked by the other children. One summer, between kindergarten and first grade, at dusk Zachary was riding in the front seat of a car with his mother on a trip to his grandparents house. All of a sudden a drunk driver swerved

into their lane causing the mother to quickly jerk the car to the side of the road. She lost control and the car hit a tree. The mother broke her leg in the accident and Zachary, thankfully in a seat belt, hit his head against the side window. Zachary was unconscious, but only for about 10 minutes.

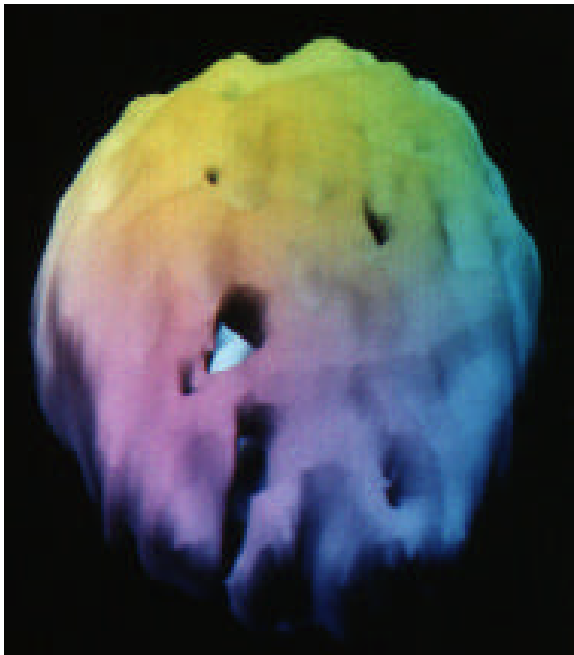Initially, they were glad to just be alive and Zachary and his mother became even closer than before. About six weeks later, however, Zachary's behavior began to change. He exhibited aggressive behavior, breaking his own toys and hurting his younger brother. He began swearing, which was a new behavior for him. He blurted out statements at inappropriate times and interrupted frequently. He became rude, contrary, argumentative and conflict seeking. He lost his friends at school the next year because he would say things that would hurt their feelings. He started to tease the two cats at home, so much so that they started to avoid him whenever he came into the house. Six months after the accident his mother knew that there was something seriously the matter. She brought him to a counselor who thought the problem was psychological, as a result of the accident. The counselor thought that Zachary and his mother were too close and developed strategies to help Zachary become more independent. That only seemed to make things worse. After two years of counseling, which didn't seem to help much, the mother consulted Zachary's her pediatrician. He diagnosed Zachary with ADD and put him on Ritalin. But it didn't help very much. In fact, it only seemed to make him more aggressive. When Zachary was brought to see me at age 9, I thought he might have a chronic post concussive syndrome, secondary to the accident. His brain SPECT study revealed marked decreased activity in the left pfc and decreased activity in the left occipital cortex, indicating both a front and back injury (common in head injuries). In addition, he had decreased activity in his left temporal lobe. Given this constellation of findings I put him on a combination of medication (an anticonvulsant, to stabilize his aggressiveness and help his temporal lobe function, and amantadine [Symmetrel] to help with focus, concentration and impulse control). He was also placed in a special class at school and given cognitive retraining exercises. Over the next several months his behavior began to improve and he was able to live at home.



*front on surface view
notice the dented area in the left anterior frontal pole*

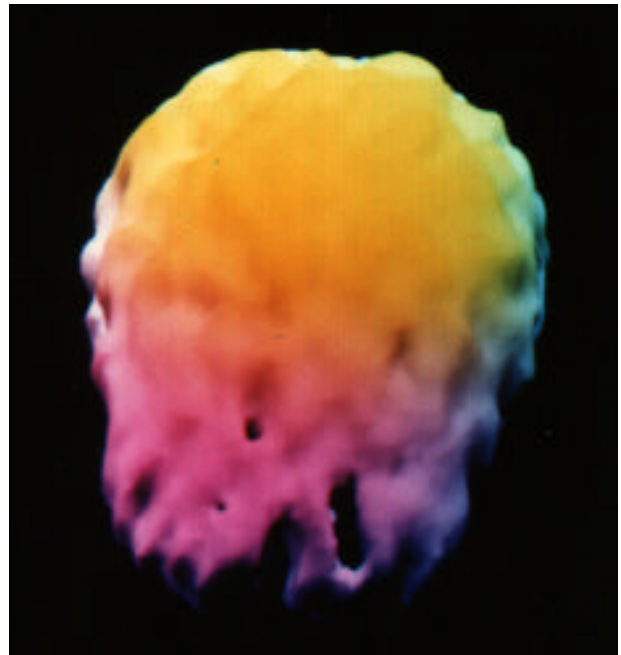


top down surface view
notice marked overall decreased activity
43 year male, motorcycle accident



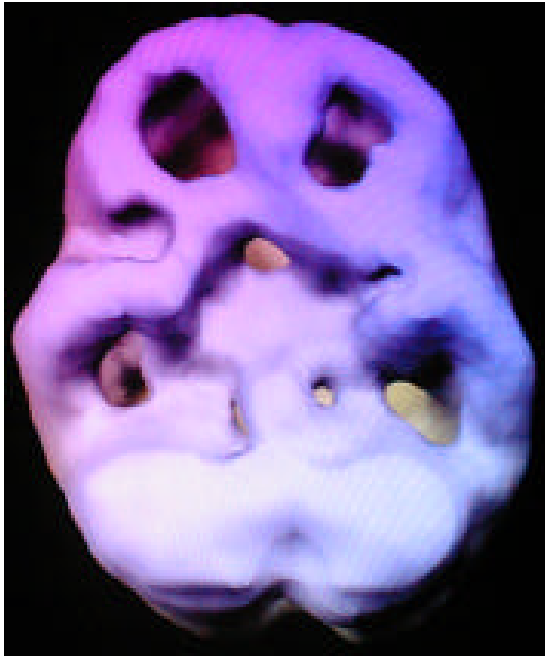top down surface view

28 y/o male bicycle accident, no helmet
 problems with impulsivity and concentration



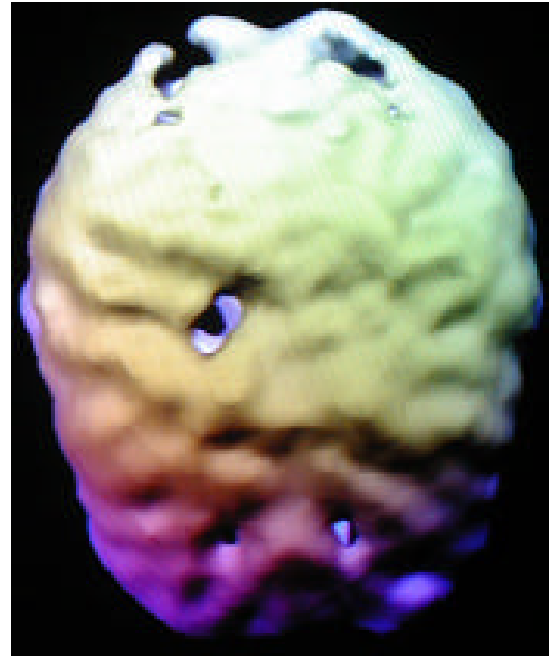
top down surface view

26 y/o rollerblade accident, no helmet
 executive function problems, suicidal ideas



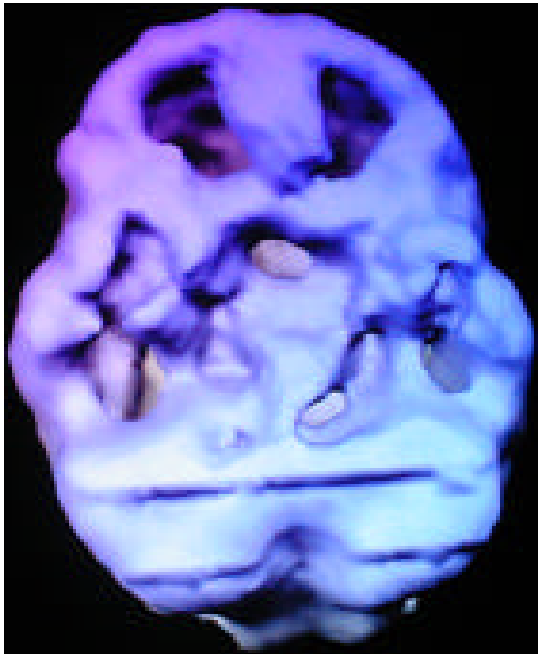
underside surface view

15 y/o horseback riding accident
memory, concentration and school problems

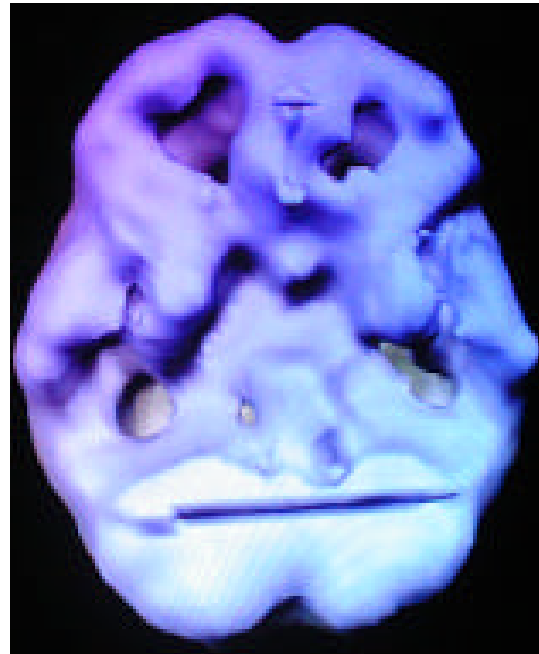

top down surface view

26 y/o bar fight, hit with large mirror
executive function problems, note contra
coup injury to frontal and occipital lobes

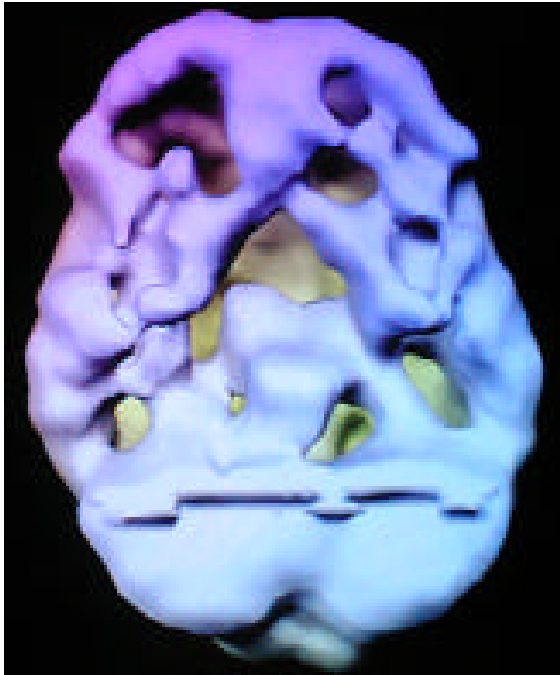

underside surface view



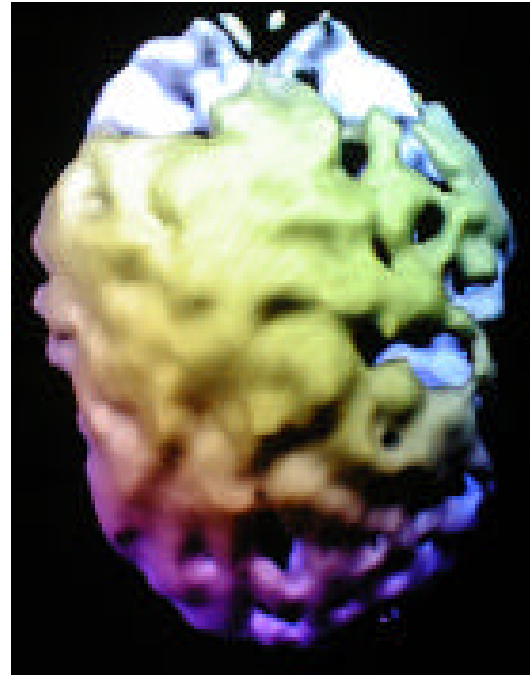underside surface view

62 y/o fall from a ladder



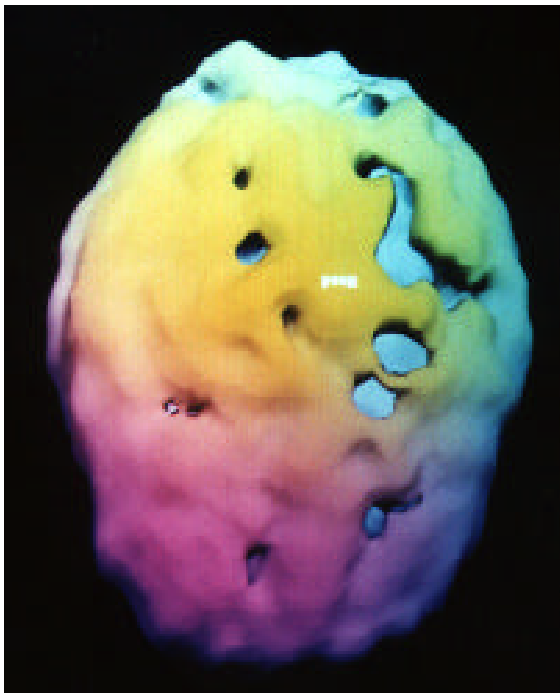
severe memory problems
underside surface view

36 y/o car accident



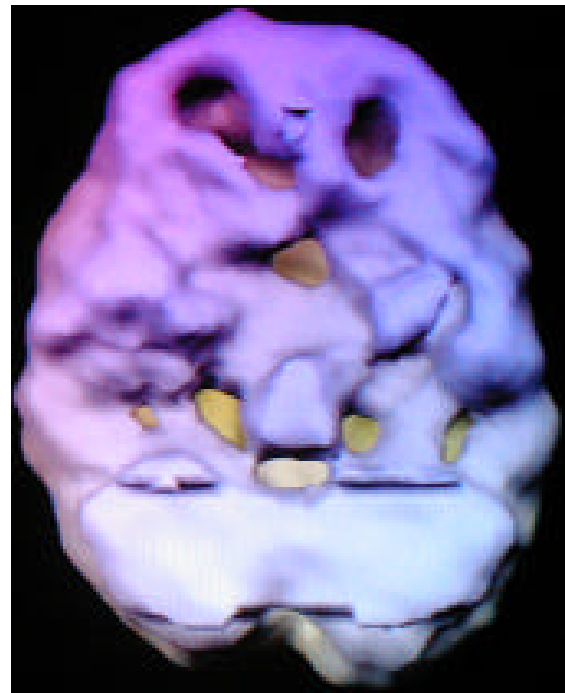memory and temper problems
top down surface view

22 y/o diving accident
memory, concentration and mood problems



top down surface view

16 y/o fell down stairs at age 3
school failure, aggression, in jail for rape

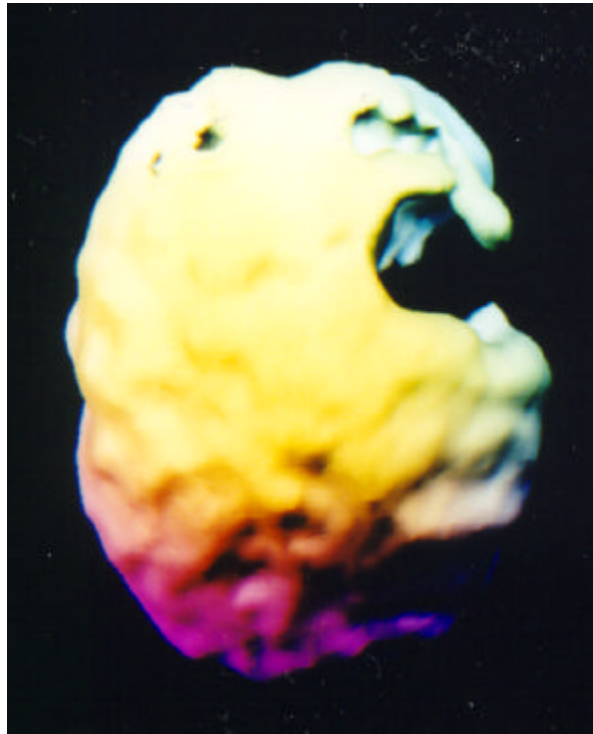


underside surface view

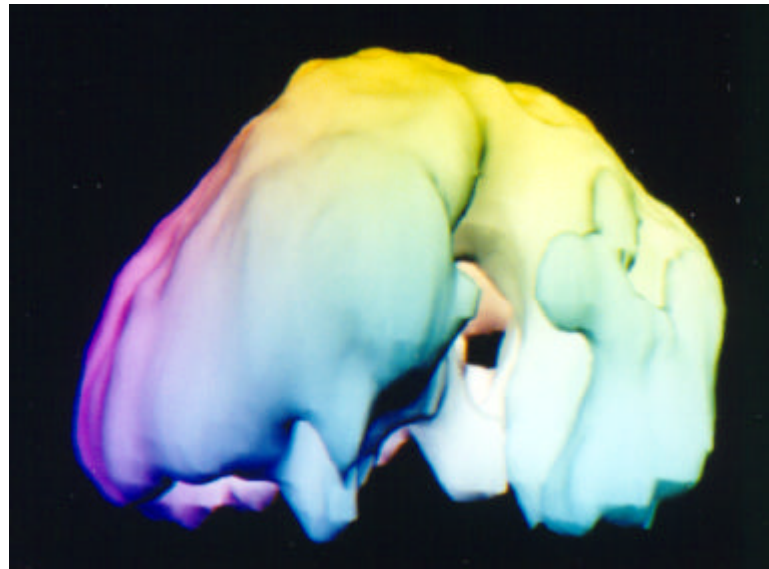
21 y/o tackle football concussion
aggression problems

10 y/o fell off jungle gym
school failure, temper problems

Fall from Roof



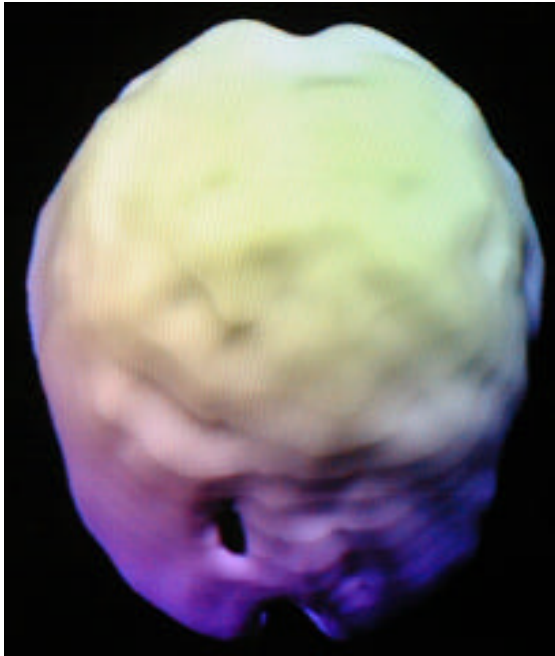
*top down surface view
note large defect left parietal area*



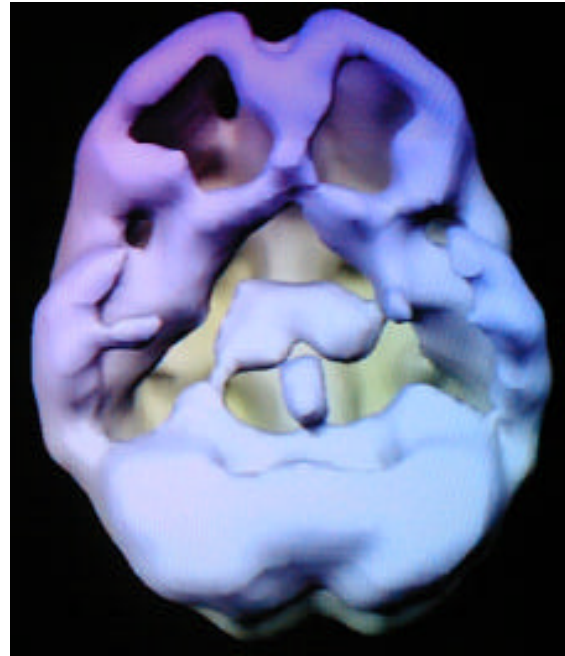
*left side surface view
note large defect left parietal and temporal lobe area*

48 year old male roofer who fell 25 feet off a roof. Subsequently, he had problems with speech, listening, memory, concentration and temper problems. His wife divorced him.

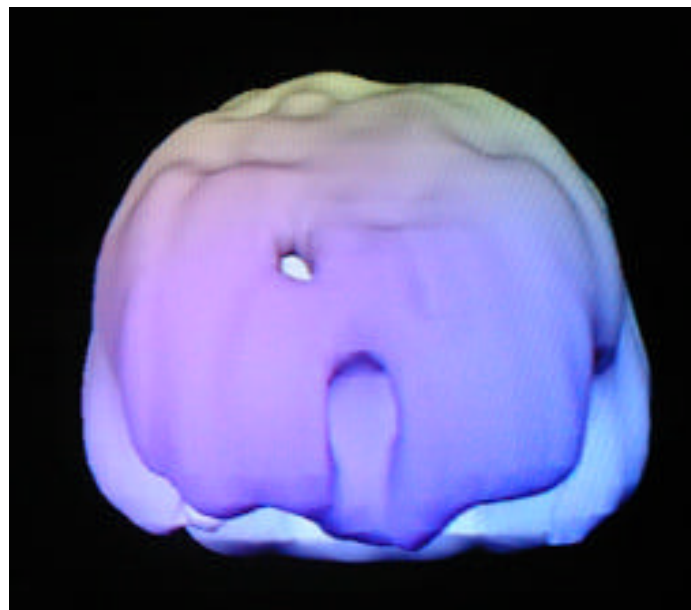
Fall from Ramp Onto Concrete



*top down surface view
note marked decreased prefrontal activity*



*underside surface view
marked overall decreased activity*



*underside surface view
marked decreased prefrontal area*

22 year old female fell down a ramp head first onto the concrete. Subsequently, she had problems with impulse control, concentration and motivation.

Section 7

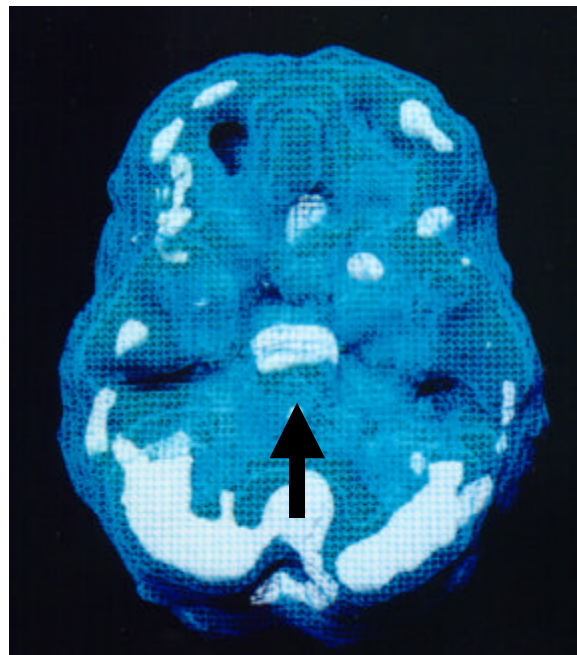
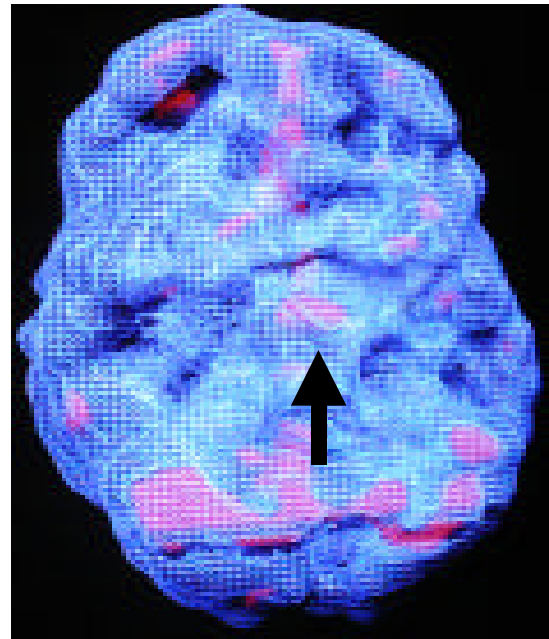
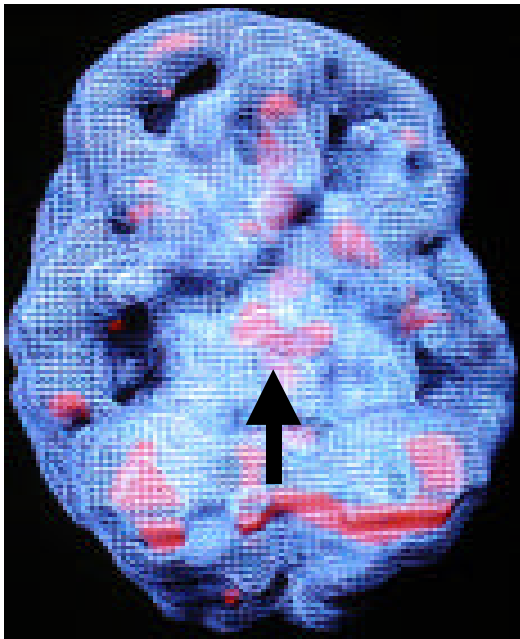
IMAGES OF DEPRESSION

Decreased prefrontal cortex activity at rest, especially on the left side is a consistent SPECT finding in depression. The severity of depression is often related to the degree of frontal hypometabolism. Several studies have indicated that the hypometabolism normalizes after treatment if the patient's mood improved. Researchers have also seen increased limbic system activity as well in depression (thalamus, amygdala, cingulate gyrus and deep temporal lobes). When depressed patients perform a concentration task the left prefrontal cortex often activates to normal levels, differentiating depression from attention deficit disorder which often shows normal activity at rest and decreased prefrontal cortex activity with concentration.

SPECT can be helpful in the diagnosis and treatment in complex or resistant depressive disorders by differentiating it from other disorders, enhancing compliance by the patient being able to “see the changes in the brain,” and by subtyping depression. Here are three subtypes that one of the authors has identified.

- Decreased prefrontal cortex activity with increased deep limbic system (thalamus) activity. This subtype is often associated with moodiness, negativity, low energy, sleep and appetite problems and poor concentration. It often responds best to dopaminergic or noradrenergic interventions such as buprion, imipramine or desipramine.
- Increased anterior cingulate (this part of the brain is heavily innervated with serotonergic nerve fibers), thalamus and basal ganglia activity. This subtype is often associated with sadness, negativity, irritability, worrying, cognitive inflexibility, worrying and getting stuck or locked into negative thought patterns. It often responds best to the serotonergic antidepressants such as fluoxetine, sertraline, paroxetine and venlafaxine.
- Decreased prefrontal cortex activity with increased or decreased temporal lobe activity. This is often the most serious subtype and it is often associated with sadness, irritability, rage (toward others or self in suicidal behavior), mild paranoia, atypical pain (atypical headaches or abdominal pain) and insomnia. We have seen this subtype often made significantly worse by serotonergic medications and it is often helped by anticonvulsants, such as gabapentin or divalproate.

1. Decreased prefrontal cortex activity with increased deep limbic system activity.

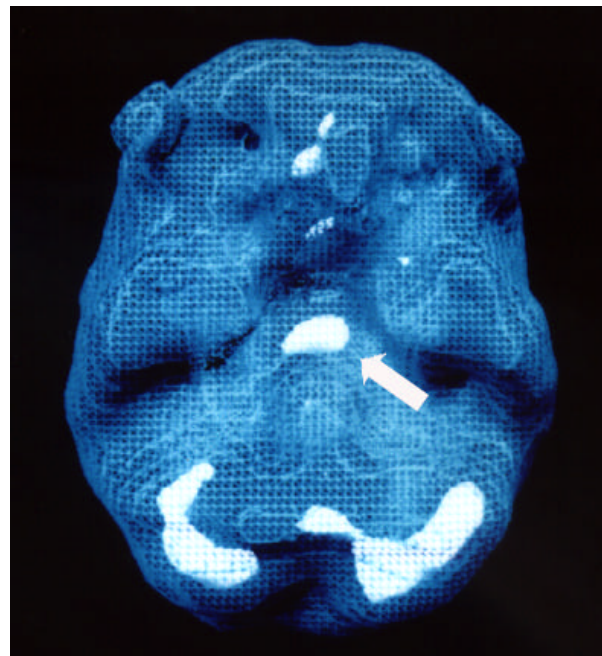


underside active views
notice increased deep limbic activity

Here is an example of deep limbic dysfunction. Leigh Anne came to see me fifteen months after the birth of her first child. Several weeks after her child was born she began experiencing symptoms of nausea, social withdrawal, crying spells and depression. Three months later she sought help through psychotherapy. But her condition did not improve. Her depression progressed to the point where she became unable to care for her daughter on a day-to-day basis. Desperate to function as the good mother she wanted to be to her child, she came to see me. After diagnosing her with major depression I placed her on Prozac and began seeing her in psychotherapy. Her symptoms remitted after only several weeks. After several months Leigh Anne discontinued treatment. She associated taking Prozac with a course of action for "a depressed person." She did not want to see herself in that light or be stigmatized with that label. For several months after stopping she had no adverse reaction. Then the symptoms returned.

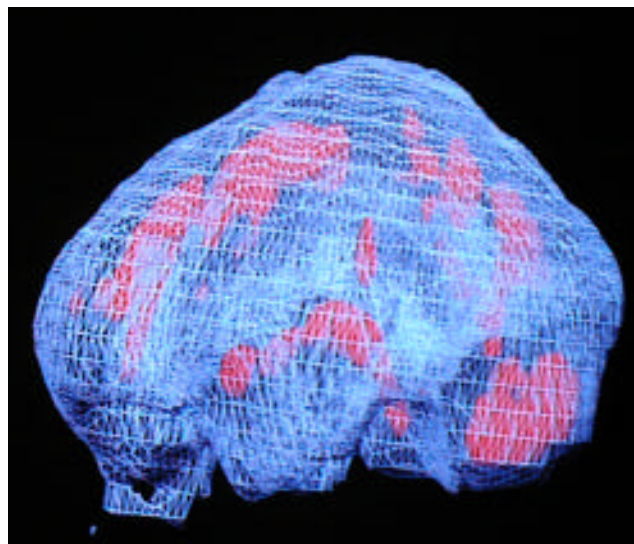

When she came to see me again Leigh Anne still didn't want to believe that anything was "wrong" with her, so she was still resistant to going back on medication. After I ordered a brain study to evaluate her deep limbic system, I was able to point out to her the marked increase in activity in that area of her brain. It provided me with the evidence needed to convince her to go back on Prozac for a while longer.

This case illustrates an important point. It has been my experience as well as that of many other psychiatrists that a patient does not necessarily have to stay on medication forever just because they have started it. However, with certain medications, like Prozac, a minimum period of treatment is necessary before it can successfully be terminated. If a depressed patient is willing to stay on their medication for long enough, about two years in this case, there is a greater chance that they can get off of it in a timely manner yet still remain free from their symptoms.



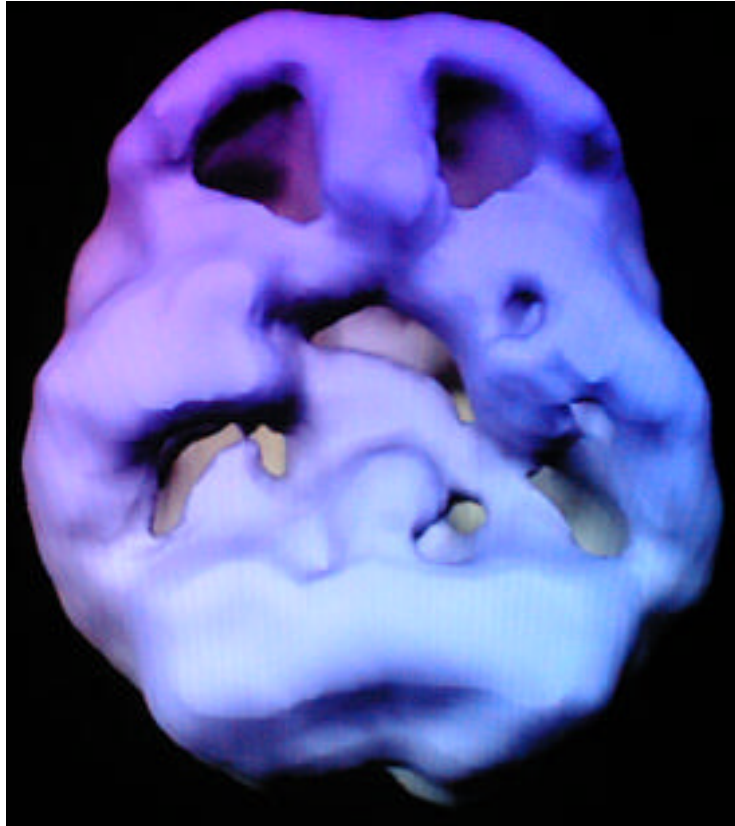
*underside active view
notice increase limbic activity (arrow)*

2. **Increased anterior cingulate (this part of the brain is heavily innervated with serotonergic nerve fibers), thalamus and basal ganglia activity.**



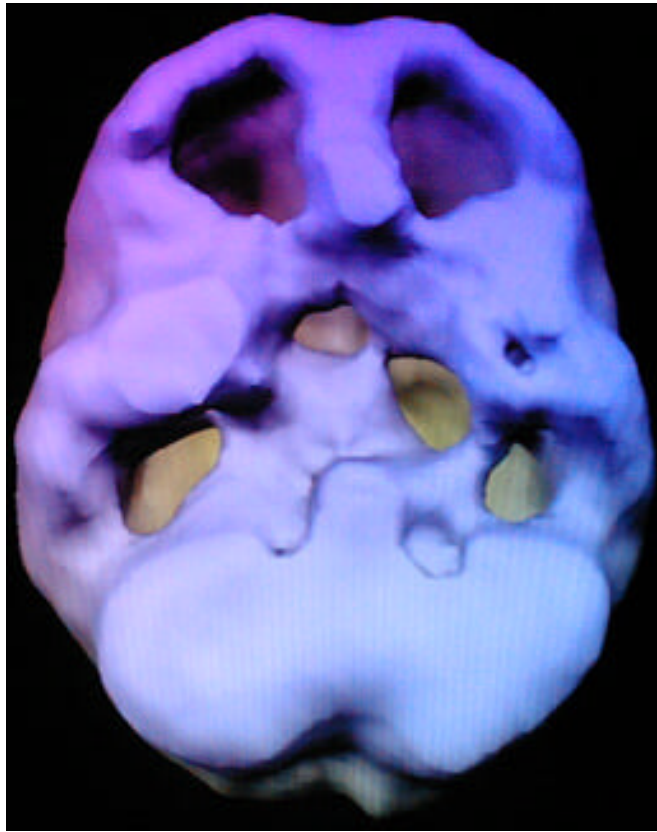
left side active views
notice increased cingulate, deep limbic and basal ganglia activity

3. Decreased prefrontal cortex activity with increased or decreased temporal lobe activity.



underside surface view
marked decreased prefrontal and temporal lobe activity

Cindy is a 17 year old who presented with symptoms of depression, suicidal thoughts and severe irritability. Serotonergic medications increased her irritability, depression and suicidal thoughts. Her SPECT study showed marked decreased activity in the left temporal lobe and prefrontal cortex. She responded positively to a combination of Lamictal and Wellbutrin and psychotherapy.



underside surface view
marked decreased prefrontal and temporal lobe activity

Summer is an 18 year old female who came for evaluation after an overdose of pills combined with alcohol in a suicide attempt. She had 4 prior suicide attempts along with a history of drug abuse, run away behavior, aggressive outbursts and school failure. Her SPECT study showed marked decreased activity in the left temporal lobe and prefrontal cortex bilaterally. She responded positively to a combination of Tegretol and desipramine and psychotherapy.

Section 8

IMAGES OF BIPOLAR DISORDER AND SCHIZOPHRENIA

Bipolar disorder has been characterized by increased activity across the cerebral cortex. Clinically, during the manic phase the scans often look hyperactive, especially in the lateral frontal cortex, lateral parietal lobes and lateral temporal lobes, focal increased uptake in the limbic system has also been noted. Differentiating the initial onset of bipolar disorder from schizophrenia is often a difficult task in an acutely psychotic individual. In schizophrenia SPECT findings have frequently reported decreased activity, especially in the prefrontal cortex. SPECT studies may provide helpful information in the differential diagnoses of these disorders. In addition, SPECT can provide useful information to patients to significantly improve compliance in disorders where compliance is a frequent serious problem. Here are several examples.

Bipolar Disorder

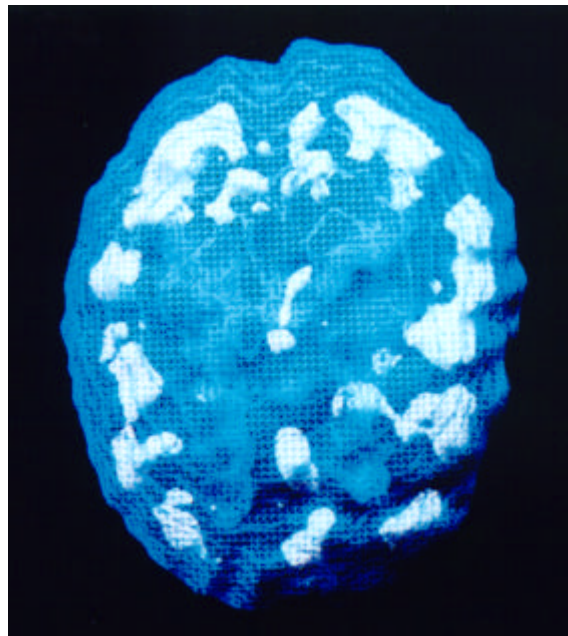
Sarah was fifty-three years old when she was admitted to the hospital under my care. Just the month before her family had her committed to another psychiatric hospital for delusional thinking and bizarre behavior -- she had actually ripped out all the electrical wiring in her home because she heard voices coming from the walls. In addition to the above symptoms, she was barely getting any sleep, her thoughts raced wildly, and she was irritable. In the previous hospital her doctor had diagnosed her with manic-depressive disorder (a cyclical mood disorder). He had placed her on lithium (an anti-manic medication) and an anti-anxiety medication. After responding well, she was sent home. But Sarah, like Leigh Anne, did not want to believe that anything was wrong with her and she stopped taking both medications. Her position was actually fortified by some members of her family who openly told her she didn't need pills, that doctors only prescribe them to force patients into numerous follow-up visits. Yet their advice was ill advised, for within weeks of stopping the treatment, Sarah's bizarre behavior returned. This was when her family brought her to the hospital where I worked. When I first saw Sarah, she was extremely paranoid. Believing that everyone was trying to hurt her, she was always looking for ways to escape the hospital. Again her thoughts were delusional; she believed she had special powers and that others were trying to take them from her. At times, she also appeared very "spacey." In an attempt to understand what was going on with her for myself, and to convince her that her problems were biological, I ordered a SPECT study.

Carrying this out did not prove easy. Our clinic tried to scan her on three separate occasions. The first two times she ripped out the intravenous line saying we were trying to poison her. The third time was a success because her sister went with her and calmed her down by talking her through the experience. While the study revealed an overall increase in activity in the deep limbic system, I found more intensity on the left side of her scan (focal increased deep limbic uptake) and a marked patchy uptake across the cortex. In other words, some areas

showed increased activity and some showed decreased. My experience told me that cyclic mood disorders often correlate with focal areas of increased activity in the deep limbic system specifically as well as a patchy uptake across the surface of the brain in general.

For Sarah's family, this was powerful evidence that her problems were biological, so that when she still refused medication, they were now willing to encourage her to go back on it. After she took their advice, her behavior normalized again and once I knew she was feeling better, more in control, I showed her the brain studies. Through a better understanding of the problem she was able to agree to follow-up visits and to stay on her medication until both she and I concurred that she could stop.

Sometimes I'll rescan a patient several months after the first time to see what difference the medication has made on the physiology of his or her brain. Although Sarah's new study showed a vast improvement from her earlier one, I still noticed an area of increased activity in the left temporal lobe, and Sarah was still complaining of symptoms of spaciness. I changed her medication to Depakote, which is primarily used as an anti-seizure medication, but has also been used for manic-depressive disorder. Not only did her psychotic symptoms remain in remission but the spaciness disappeared as well. Five years later only a small dose of Depakote has given Sarah a normal life.

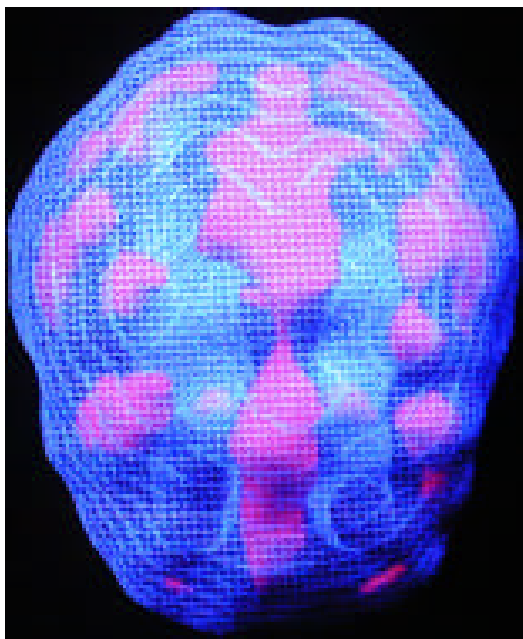


*top-down active view
note patchy uptake throughout the cortex*

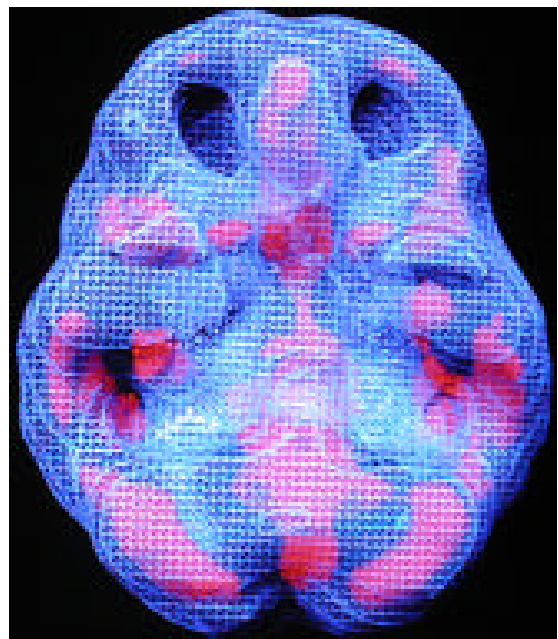
Sarah's case illustrates one of the most clinically significant problems in people diagnosed with manic-depressive illness. This disorder is usually quite responsive to medication. The problem is that when people afflicted by the disorder improve, they feel so normal they do not believe they ever had a chronic problem to begin with. It is difficult for people to accept that they have to keep taking medication when they think they no longer have a problem. Yet, as we

have seen, prematurely stopping medication actually increases their chances for relapse. Through the use of these brain studies I have been able to decrease the relapse rate of my patients by demonstrating graphically the biological nature of their disorders and the need to treat them as such. It has been a great asset to me in getting patients to cooperate in their own healing process. In addition to that, it has helped me with one other important thing: convince patient's to stop blaming themselves for their symptoms. Here are two more sets of images of Bipolar patients taken during the manic phase of the illness.

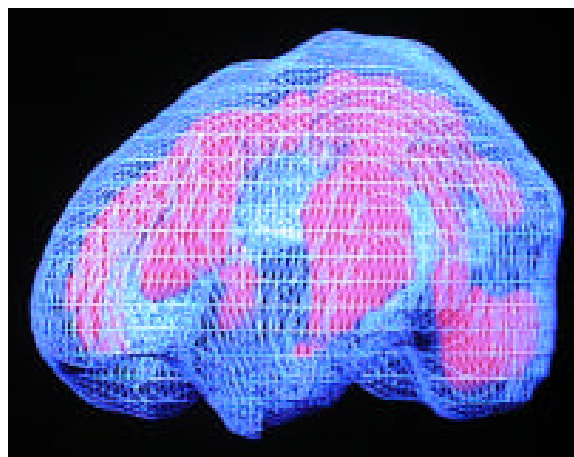
Ryan was a 20-year-old male who presented with symptoms of grandiosity, racing thoughts, decreased sleep, irritability and agitation. His parents reported there was a family history of Bipolar Disorder in his grandfather.



top down surface view



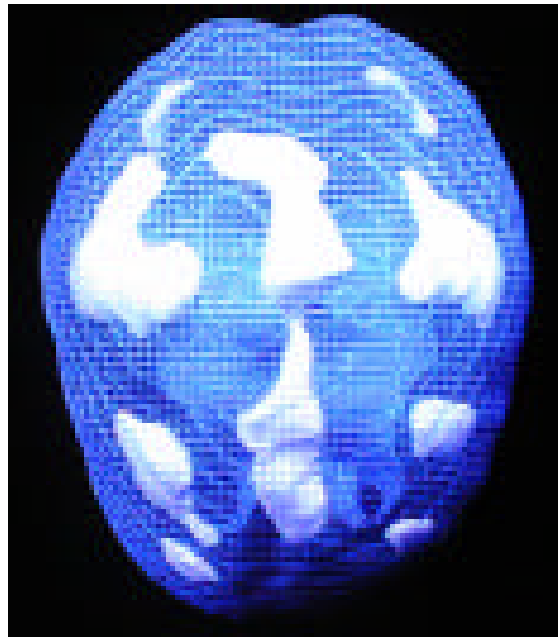
underside surface view



left side active view

note the marked increased patchy uptake throughout the cerebral cortex

Carrie was a second year college student when she first began having problems. She would go days without sleeping. She began having trouble concentrating in school and stopped going to classes. She started having sexual relationships with 4 different men and she spent all of the money she had for the school year in three months. When her parents discovered the problems they brought her in for evaluation. Carrie did not feel that anything was wrong. She felt that she had just made several poor decisions, like anyone her age. Her parents felt things were not the same. She had always been a thoughtful, responsible person prior to the last several months. A scan was ordered to help evaluate the clinical situation. It revealed marked patchy uptake throughout the cortex. Lithium was very helpful for Carrie and she was able to return to school the next semester.



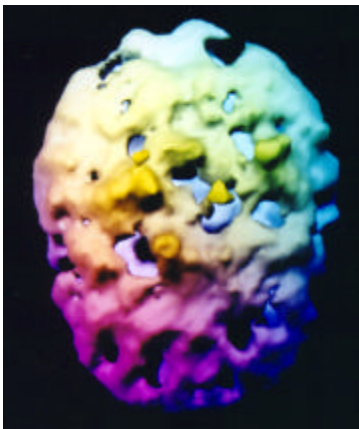
*3D top-down active view
patchy increased uptake across the cortical surface*

Schizophrenia

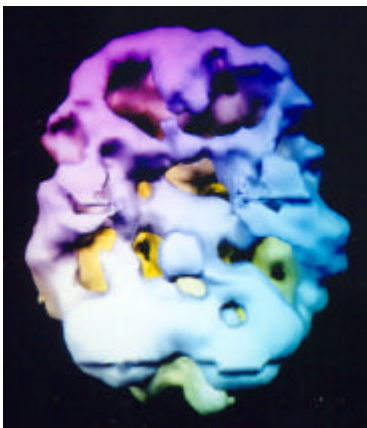
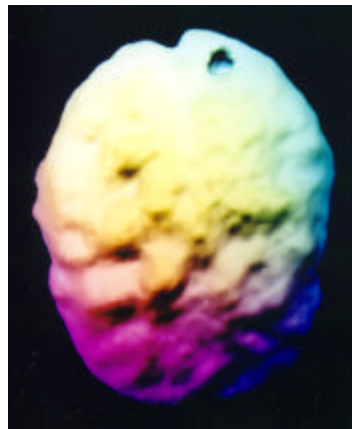
A 35-year-old man who had been living on the street was brought for evaluation by his mother. He had previously been diagnosed on many occasions with paranoid schizophrenia, but refused medication. His SPECT study revealed marked overall decreased activity throughout the cerebral cortex. Being able to see his own brain activity, represented by the 3D surface SPECT study, was helpful for him. He agreed to take his medication under his mother's supervision. One month later, after significant clinical improvement on 4 mg of risperidone a repeat SPECT study was performed which showed improved overall cerebral perfusion. Being able to see the before and after SPECT studies side by side on the imaging computer monitor again was very encouraging to the patient and helped significantly with compliance.

Paranoid Schizophrenia, before and after treatment with risperidone (top-down and underside surface views)

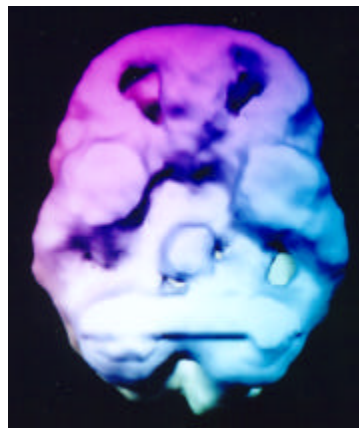Before Treatment



After Treatment



marked decreased activity
throughout the cerebral cortex

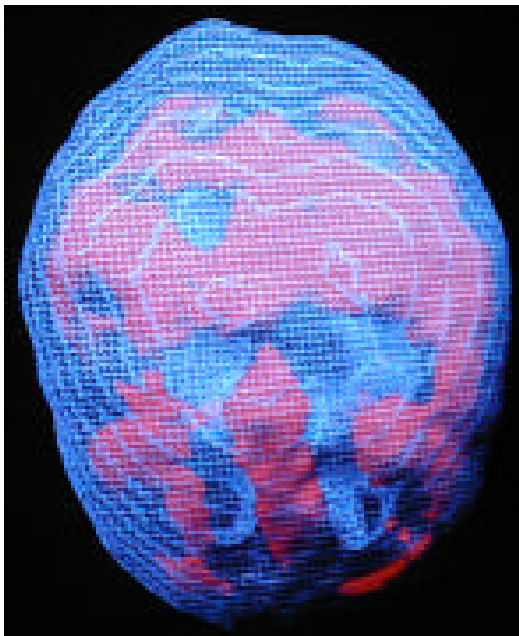


marked overall improvement
throughout the cerebral cortex

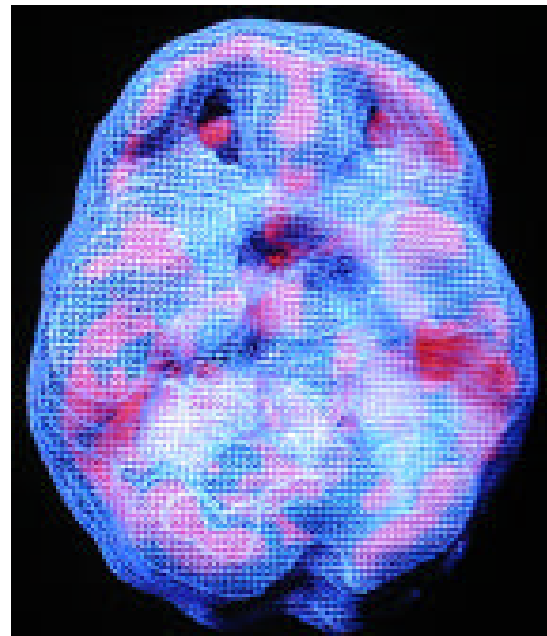
Section 9

IMAGES OF THE RING OF FIRE

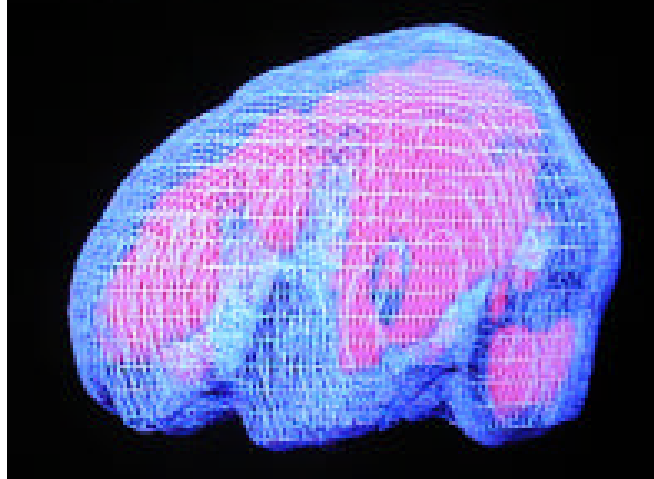
One of the new patterns we feel we have discovered is one we affectionately term the ring of fire. It consists of marked hyperactivity throughout the cortex, often in a ring like pattern. It shows the hyperfrontality pattern (increased cingulate activity with increased left and right lateral prefrontal cortex activity) frequently seen in obsessive compulsive spectrum disorders and hyperactivity in the left and right lateral parietal and temporal lobe regions. We have seen this pattern most frequently in children and teenagers. It reminds us of the patchy increased uptake seen commonly in Bipolar Disorder. We wonder if it represents a functional brain pattern for children and teens who are vulnerable to Bipolar Disorder. The children and teenagers are not what most clinicians would consider in a manic state and their symptoms may or may not cycle. In a group of 70 patients with this pattern the most common symptoms were moodiness, problems shifting attention, oppositional behavior, irritability, temper problems, hypersensitivity to noise and/or touch, inattention, distractibility and impulse control problems. This pattern seems to be made worse by psychostimulants and serotonergic agents and better by anticonvulsants, such as Depakote or Neurontin and the new antipsychotics, such as Risperdal or Zyprexa.



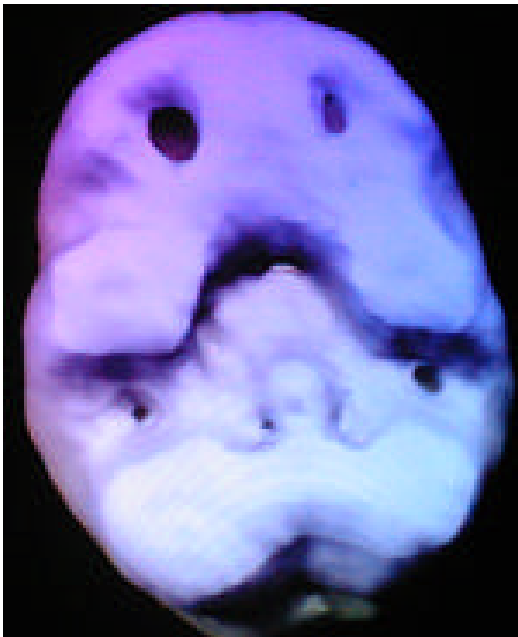
top down surface view



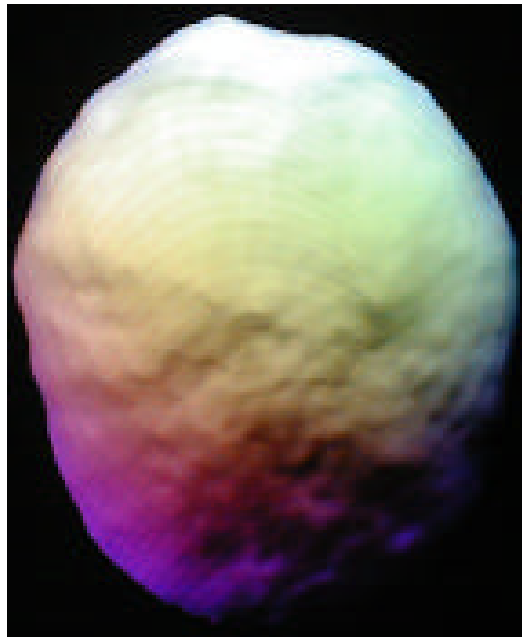
front on surface view



left side active view



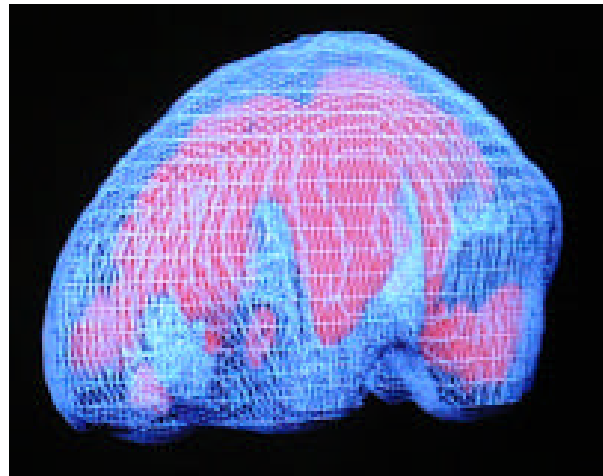
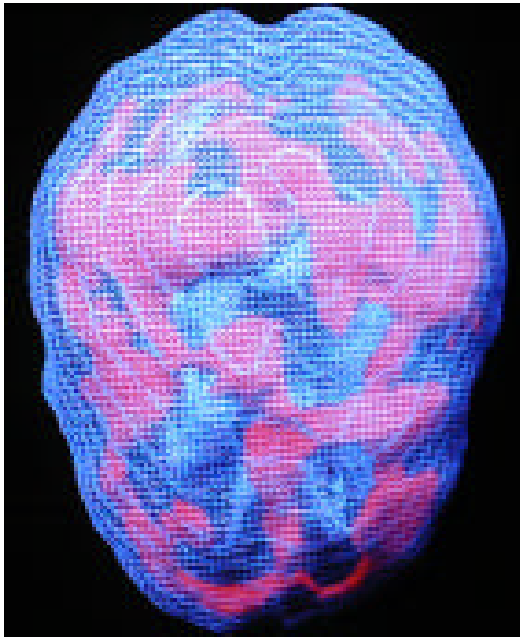
underside surface view



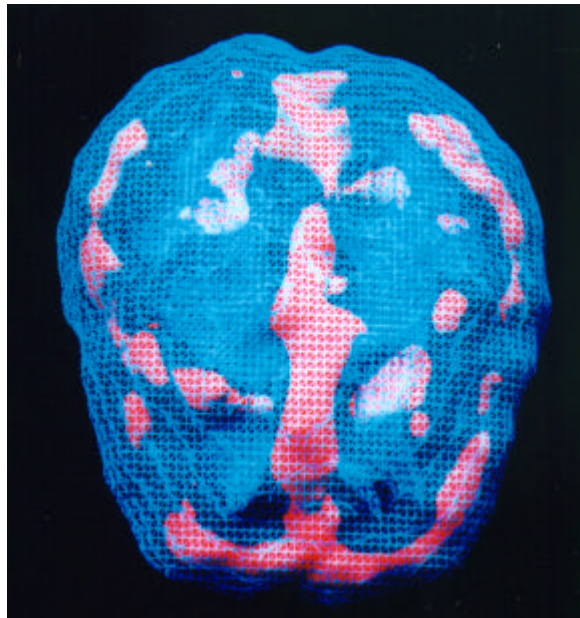
top down surface view

Notice the marked hyperactivity throughout the cerebral cortex in a “ring-like” pattern. Also note that the surface views look normal. This scan series is of a 14 year old boy who had serious problems with oppositional and aggressive behavior. His moods were erratic and he had longstanding behavioral problems despite being a very good student. There was a family history of alcohol abuse and depression. He had a very positive response to Risperdal which had a calming effect on the cerebral hyperactivity.

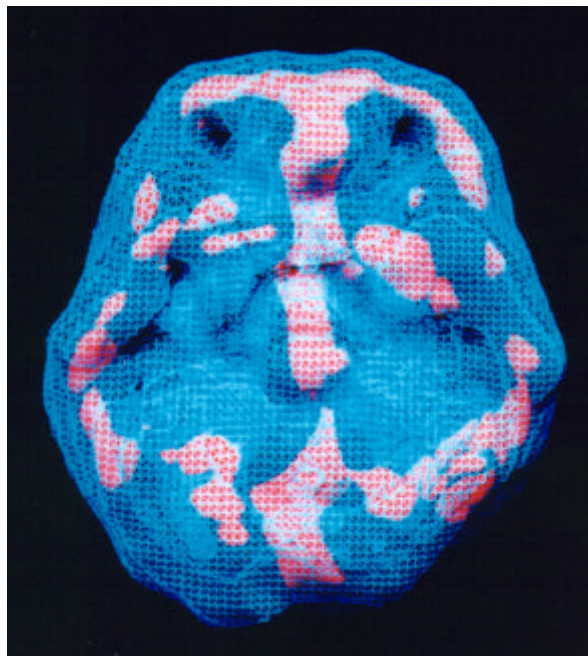
This next case series is of a 12 year old girl who was referred to the clinic for aggressive outbursts, moodiness and chronic irritability. Her pattern was similar to the one shown above and she had a similarly positive response to Risperdal.



Tanya, a 17 year old female, was brought for evaluation because of severe temper problems, conduct problems (runaway and school truancy), a 5 year history of alcohol abuse that had escalated in the prior 2 years and depression with suicidal ideation. Her parents felt her behavior was “willful” and she could change if she wanted to change. Initially they were opposed to psychiatric treatment, but reluctantly came after she had a suicide attempt. Her scan revealed marked hyperactivity throughout the cortex in a “ring of fire” pattern, along with marked increased left basal ganglia activity. She had a nice response to Neurontin and Prozac obtaining more level moods, less temper outbursts and more cooperative behavior.



top down active view



underside active view

The Ring of Fire and Alcohol Induced Violence

20-year-old single male, who often became violent when he drank alcohol, even though he reported that alcohol made him feel better. From the age of 18 to 20 he was arrested 10 times for violent, aggressive behavior, all while he was intoxicated. The arrests were mostly for drunk and disorderly in public, one was for assault his girlfriend, and the last one, which precipitated the study, was for armed robbery.

On the night of the last crime this man started drinking about 10:00 PM. He drank 750 milliliters of peach schnapps within a half-hour followed by 40 ounces of malt liquor beer the next half-hour. He then “drag raced” a friend on the street and became involved in a motor vehicle accident. He fled the scene on foot. A short while later he called a taxicab. He had the cab driver drive him and a friend around for about 20 minutes. At exactly 12:10 AM he pointed a loaded gun at the cab driver’s head and demanded all his money. He got \$25 and ran away on foot. The next morning, after sobering up, he turned himself into the police.

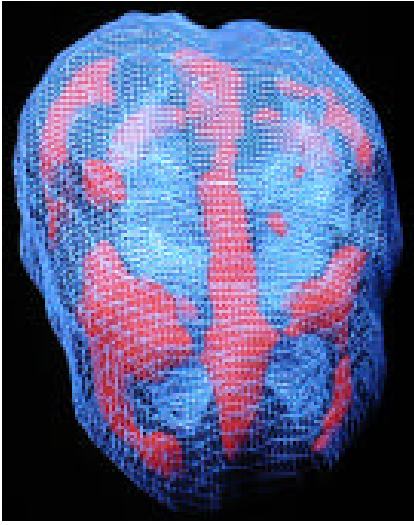
At the request of his defense attorney SPECT imaging was performed. Since he seemed to only be aggressive when he drank alcohol he was imaged with and without alcohol. The first SPECT study was performed “drug and alcohol” free. The second study was performed after he consumed 750 milliliters of peach schnapps, followed by 40 ounces of malt liquor beer (the alcohol was the same brand he drank on the night of the crime consumed in the same time frame).

The “non-alcohol” study revealed marked overactivity in the cingulate gyrus, right and left frontal lobes, right and left parietal lobes and the right temporal lobe – the “ring of fire.” As noted, these findings are often associated with anxiety, cyclic mood tendencies and irritability.

For the alcohol study, his blood alcohol level was 0.2g/dl(%). This study showed an overall dampening effect on the hyperactive areas of the brain (frontal, parietal and right temporal lobe), with only the cingulate gyrus showing excessive activity (although significantly less activity than on the non-alcohol study). In addition, the right and left prefrontal cortex was now significantly underactive, as were the left and right temporal lobes.

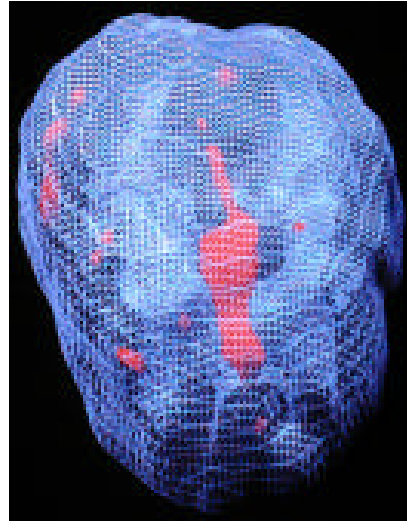
Given the marked hyperactivity in his brain in a drug and alcohol free state, along with his report that he felt more relaxed when he drank, it is not unreasonable to assume he may have been using alcohol as a way to settle down his brain and feel more comfortable (**self-medication**). Unfortunately, by self-medicating, he was **inducing a “violent” pattern** in his brain. Increased cingulate activity, abnormal left temporal lobe activity and decreased prefrontal cortex activity is the triad of symptoms that have been found in violent patients. He drank himself into a violent state as a way to medicate underlying abnormalities in his brain.

No Alcohol

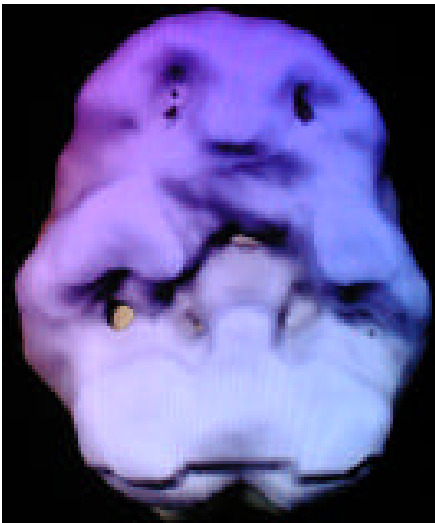

top-down active view
ring of fire pattern

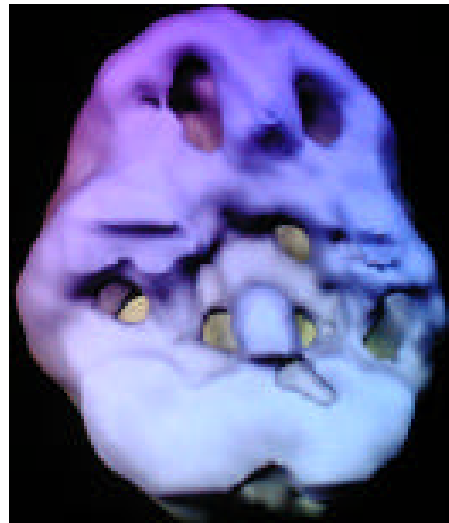
Alcohol Intoxicated State



top-down active view
overall dampening effect on the brain
still increased cingulate activity



underside surface view
good overall activity without alcohol



underside surface view
marked decreased in temporal lobes
(tendencies toward aggression),
marked decreased prefrontal cortex
(no internal supervision)

Section 10

IMAGES OF PMS Is It Real? You Bet!

Over the past years we have scanned many women with PMS just before the onset period, during the worst time of their cycle, and then again a week after the onset of their period, during the best time. Most often when PMS is present we see dramatic differences between the scans. When a woman feels good, her deep limbic system is calm and cool and she has good activity in her temporal lobes and prefrontal cortex. Right before her period when she feels the worst her deep limbic system is often overactive and she has poor activity in her temporal lobes and prefrontal cortex!

I have seen two PMS patterns, clinically and on SPECT, that respond to different treatments. One pattern is focal increased deep limbic activity often accompanied by temporal lobe hypoperfusion that correlates with cyclic mood changes. When the limbic system is more active on the left side it is often associated with anger, irritability and expressed negative emotion. When it is more active on the right side it is often associated with sadness, emotional withdrawal, anxiety and repressed negative emotion. Left-sided abnormalities are more a problem for other people (outwardly directed anger and irritability), while right-sided overactivity is more an internal problem. Focal deep limbic and temporal lobe findings, worse during the premenstrual period, often respond best to lithium or anticonvulsant medications, such as Depakote, Neurontin, Lamictal or Tegretol. These medications tend to even out moods, calm inner tension, decrease irritability and help people feel more comfortable in their own skin.

The second PMS pattern that I have noted is increased deep limbic activity in conjunction with increased cingulate gyrus activity. The cingulate, as we will see, is the part of the brain associated with shifting attention. Women with this pattern often complain of increased sadness, worrying, repetitive negative thoughts and verbalizations (nagging) and cognitive inflexibility. This pattern usually responds much better to medications which enhance serotonin availability in the brain, such as Zoloft, Paxil or Prozac. Here are several examples.

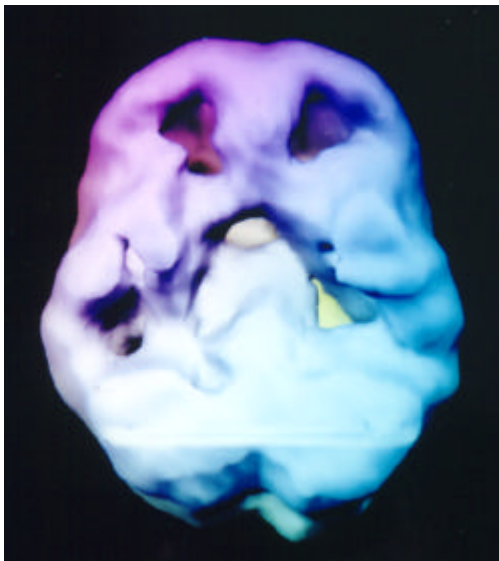
Haley

Haley is a 12-year-old girl who presented to the clinic with violent mood swings, aggressive behavior, prolonged tantrums, depression and oppositional behavior. Her symptoms primarily occur several days before and after the onset of her menstrual cycle. By the first week after the start of her period she is markedly improved, more compliant, more positive and easier to get along with. In order to help understand the underlying physiological abnormalities in her brain a SPECT series was performed during the worst time of her cycle (day 3 of her menstrual cycle) and during the best time of her cycle (day 10).

Haley's study during the worse part of her cycle was very abnormal with marked overactivity of the cingulate gyrus (associated with obsessive thinking and problems shifting attention), significant decreased temporal lobe activity (associated with aggressive thoughts, hypersensitivity to others, memory problems and mood instability) and marked decreased prefrontal cortex activity (associated with problems of impulsivity, attention span and self-supervision).

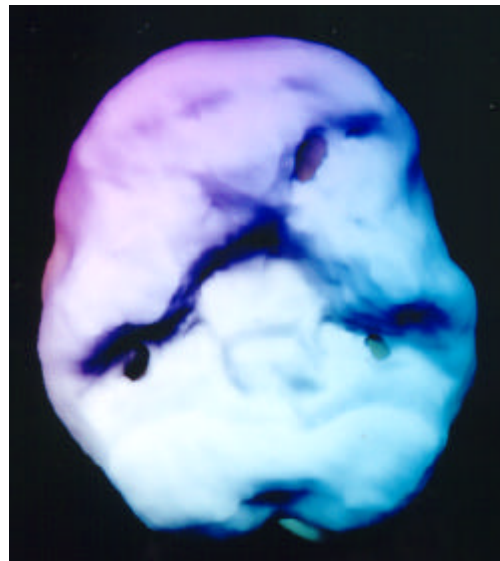
The SPECT study during the best time of her cycle markedly improved with decreased cingulate activity and improved function in the temporal lobes and prefrontal cortex. HL had a positive response to medication geared toward stabilizing the temporal lobes (Neurontin), calming cingulate hyperactivity (Zoloft) and enhancing prefrontal cortex function (Adderall). During the worst time of her cycle she also takes Risperdal to calm the aggressive behavior.

Day 2 of Cycle During Worst Time



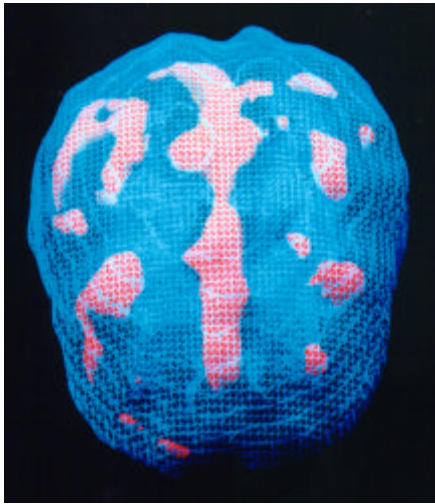
underside surface view
notice marked decreased prefrontal
cortex and temporal lobe activity

Day 10 of Cycle During Best Time

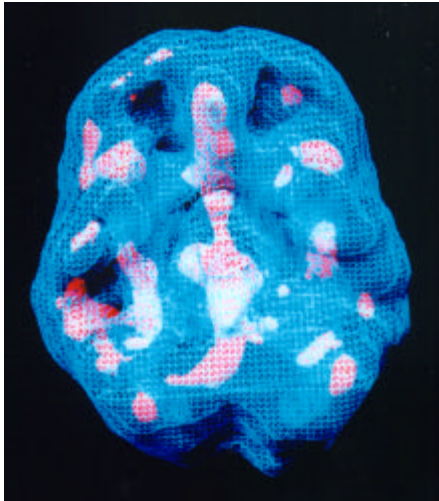


underside surface view
notice marked overall improvement

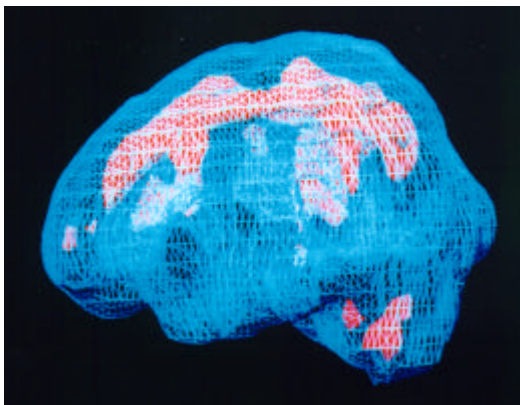
During Worst Time



top down active view



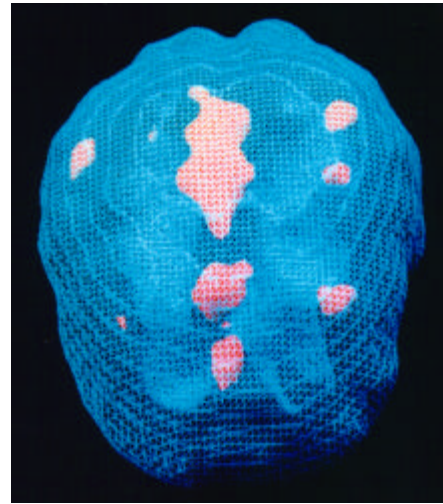
underside active view



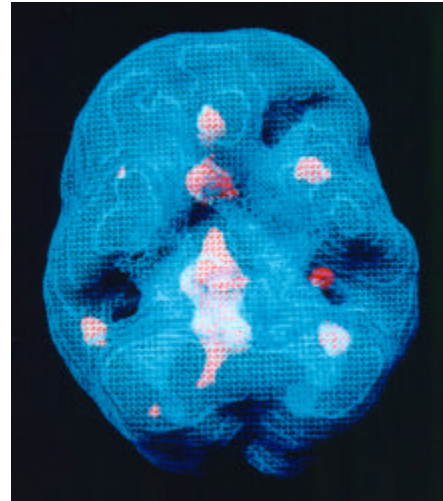
side active view

notice marked increased cingulate activity

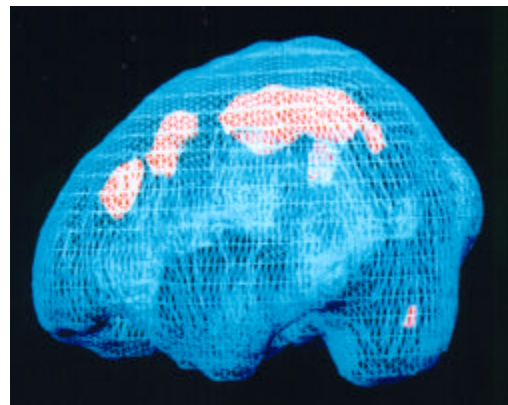
During Best Time



top down active view



underside active view



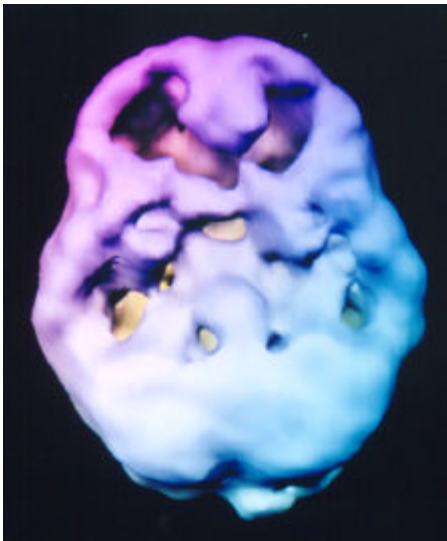
side active view

notice calming of cingulate hyperactivity

Andrea

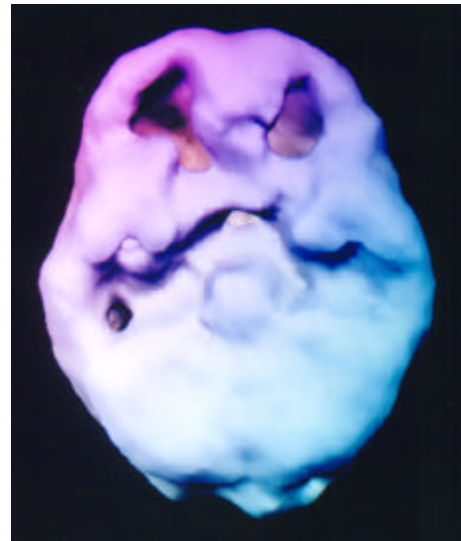
Andrea is a 25-year-old female who has been diagnosed with severe PMS and ADD. Seven to ten days before the onset of her menstrual cycle she experiences moodiness, irritability, hypersensitivity to others, anxiety and increased alcohol consumption. These symptoms decrease significantly several days after the onset of her menstrual period.

Just Before Period During Worst Time

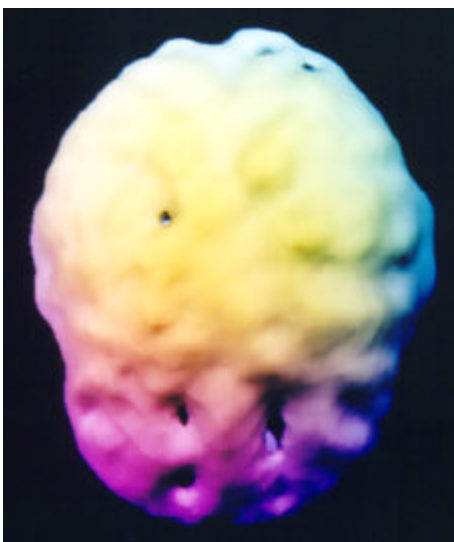


underside surface view
marked decreased prefrontal and temporal activity

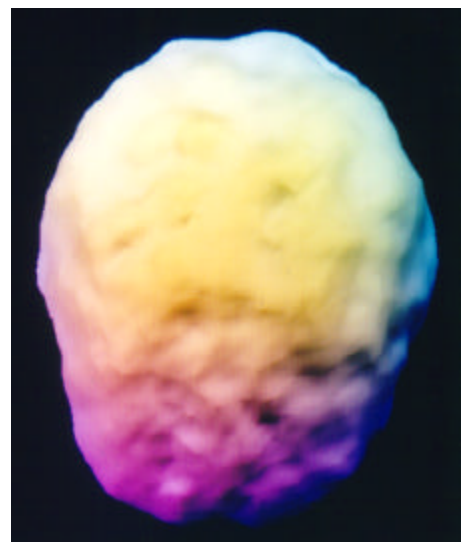
1 Week After Period During Best Time



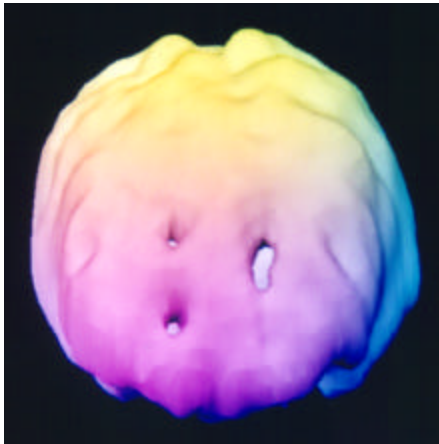
underside surface view
notice marked overall improvement



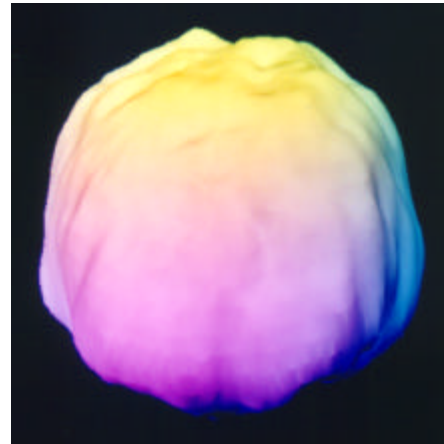
top down surface view
notice decreased prefrontal activity



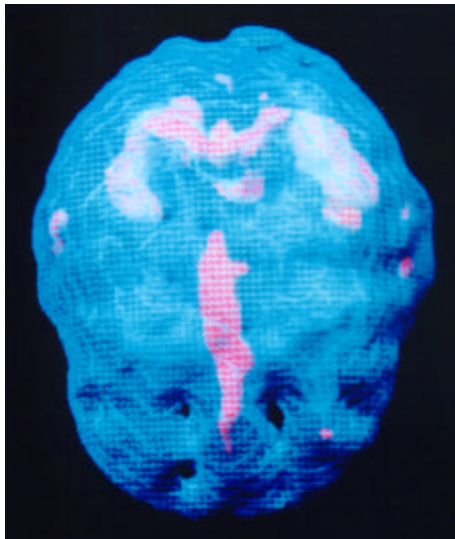
top down surface view
notice fuller prefrontal activity



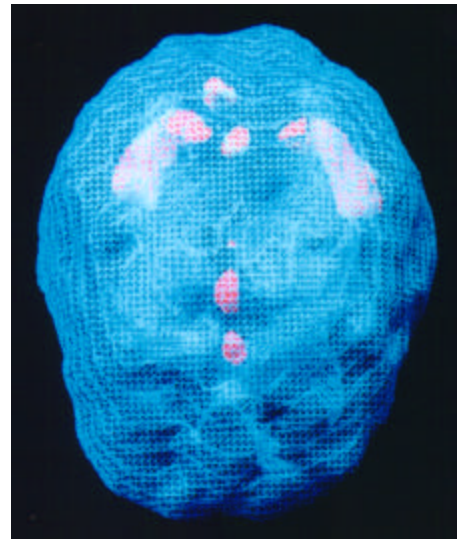
front on surface view
notice decreased prefrontal activity



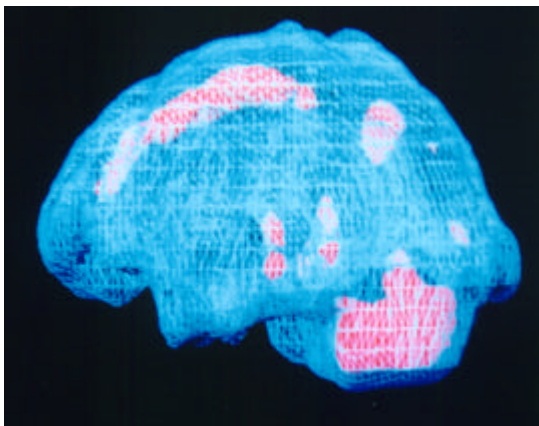
front on surface view
notice fuller prefrontal activity



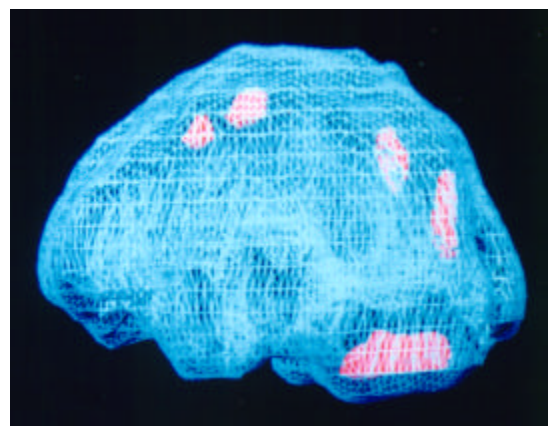
top down active view
notice marked increased cingulate activity



top down active view
notice calming of cingulate hyperactivity



side active view
notice marked increased cingulate activity

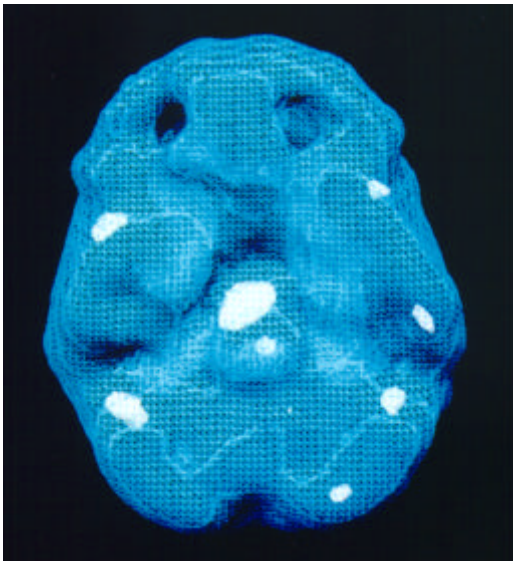


side active view
notice calming of cingulate hyperactivity

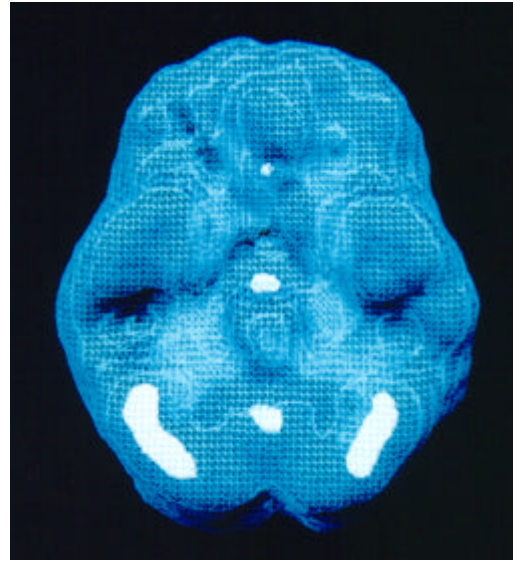
Michelle

On three separate occasions Michelle, a 35-year-old nurse, left her husband. Each time she left him it happened within the ten days before the onset of her menstrual period. The last time she left him, her irritability, anger and irrational behavior escalated to the point where she attacked him with a knife over a minor disagreement. The next morning, her husband was on the phone to my office. When I first met Michelle, it was several days after her menstrual period had started and things had significantly settled down. The severe temper outbursts were usually over by the third day after her period started. In my office she appeared to be a gentle, soft-spoken woman. It was hard for me to imagine that this woman had only days before gone after her husband with a carving knife. Because her actions were so serious, I decided to perform two brain SPECT studies on her. The first one was done four days before the onset of her next period -- during the roughest time in her cycle -- and the second one was done eleven days later -- during the best time of her cycle.

My colleagues and I have observed that left-sided brain problems often correspond with a tendency toward significant irritability, even violence. On Michelle's premenstrual brain study before the onset of her period her limbic system (the mood control center) near the center of her brain was significantly overactive, especially on the left side. This "focal" limbic finding (on one side as opposed to both sides) often correlates with cyclical tendencies toward depression and irritability. There was a dramatic change in her second scan taken eleven days later when Michelle was feeling better. The limbic system was normal!



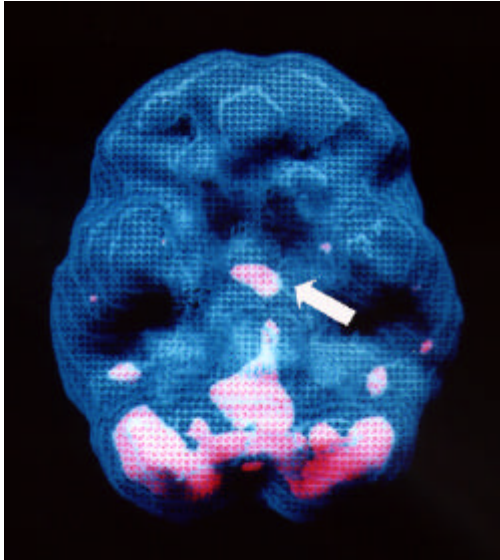
underside active view
notice marked increased limbic activity



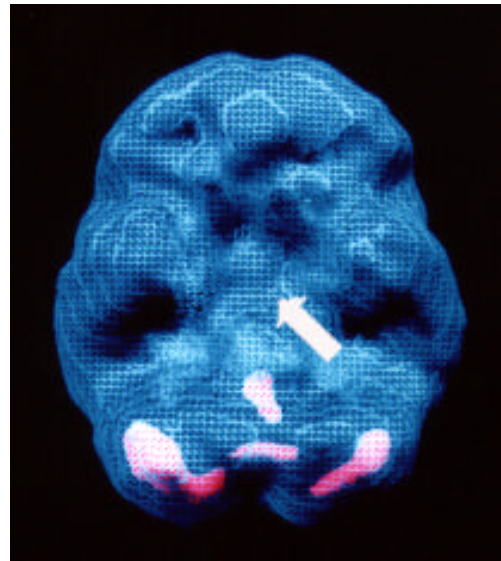
underside active view
notice calming of limbic hyperactivity

JJ

JJ is a 44 year old woman who experiences severe symptoms before the onset of her period. These symptoms include moodiness, anger, sugar cravings, insomnia and anxiety. These symptoms abate several days after the onset of her period.



underside active view
notice marked increased limbic activity



underside active view
notice calming of limbic hyperactivity

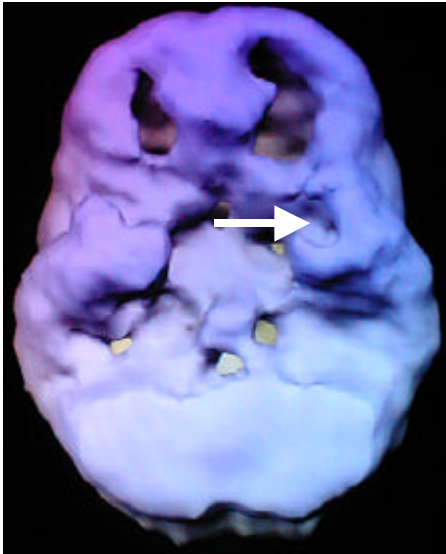
Chris

Chris was a thirty-eight-year-old married female referred for evaluation of suicidal thoughts, depression and temper flares. She also experienced problems with anxiety, excessive tension and overeating. These problems occurred primarily during the last 10 days of her menstrual cycle and abated two to three days after the onset of menses. On three separate occasions she left her husband within the 10 days prior to the onset of her period, on one occasion, she attacked him physically. The patient and her husband confirmed the cyclic changes to her symptomatology. Both the patient and her husband kept a symptom log over the next month and she gave consent to participate in the study.

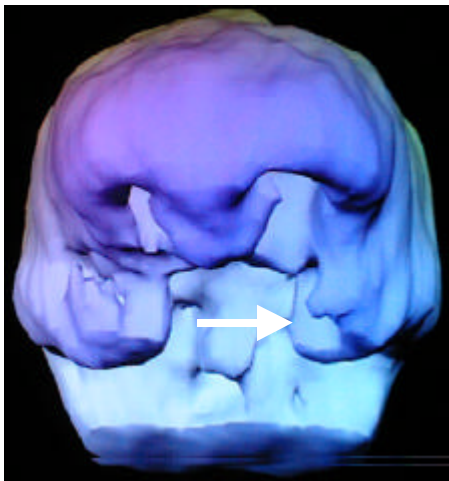
On day 27 (of a 29 day cycle) Chris called the clinic, saying that she was having problems with suicidal thoughts and depression. She was scanned the same day. Her SPECT study revealed significant increased activity in the anterior cingulate gyrus and marked decreased activity in the left temporal lobe and prefrontal cortex bilaterally. She was then scanned on day 8 of the next menstrual cycle when she was symptom free. Her follow-up scan revealed improved temporal lobe and prefrontal cortex function but persistent cingulate hyperactivity.

Due to the clear temporal lobe pathology Chris was placed on divalproate which stabilized her temper outbursts and suicidal thoughts. Sertraline was then added a month later due to persistent premenstrual sadness. Twenty-four cycles later she remains symptom free.

Day 27
During Worst Time

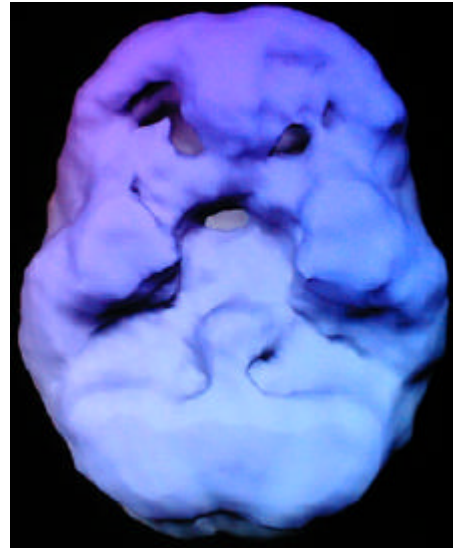


underside surface view
marked decreased prefrontal
and left temporal lobe activity

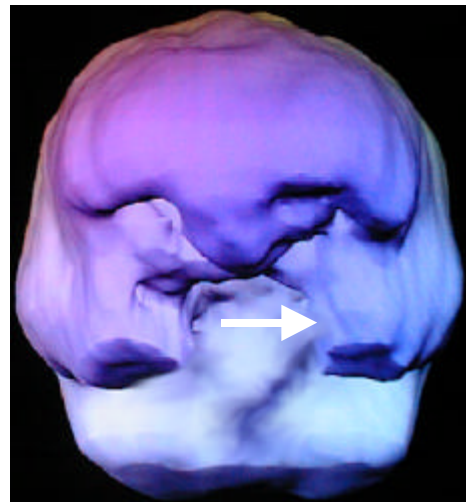


front on surface view
notice decreased prefrontal and
left temporal lobe (arrow) activity

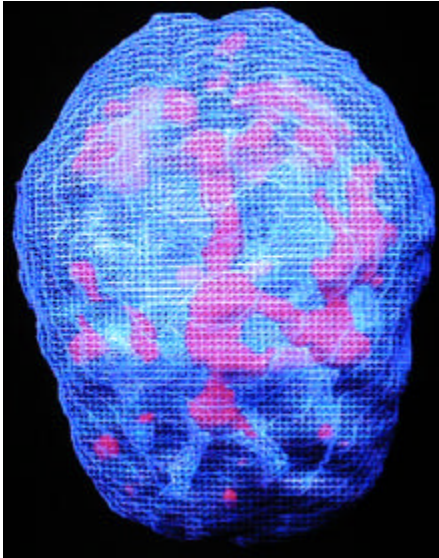
Day 8
During Best Time



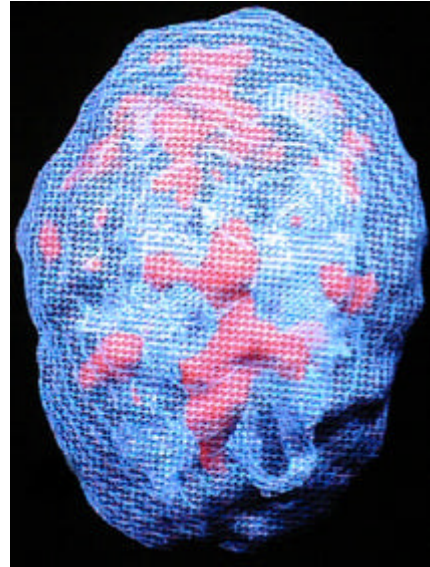
underside surface view
notice marked overall improvement



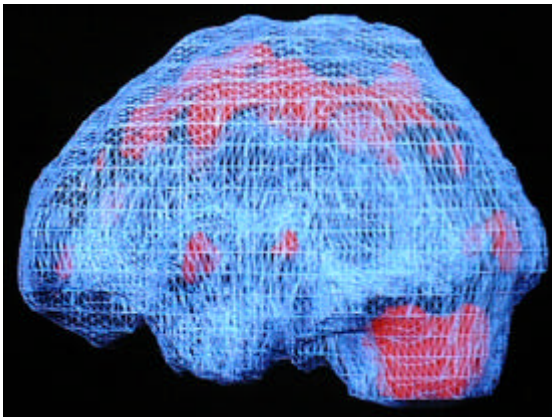
front on surface view
notice fuller prefrontal and
left temporal lobe (arrow) activity



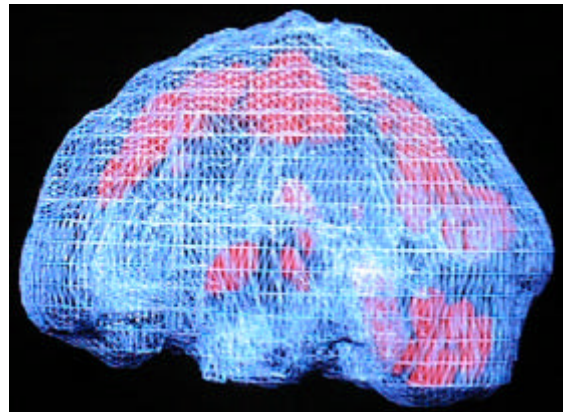
top down active view
notice marked increased cingulate activity



top down active view
continued cingulate hyperactivity



side active view
notice marked increased cingulate activity



side active view
continued cingulate hyperactivity

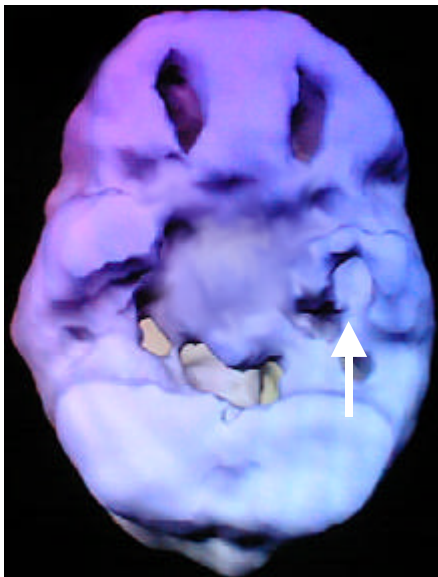
Danielle

Danielle was a thirty-three-year-old married female referred for evaluation of suicidal thoughts, depression, anxiety and irritability. These problems occurred predominantly during the last week her menstrual cycle and significantly let up several days after the onset of menses. She had experience a post-partum depression after the birth of one child but not after the birth of her other 2 children. The patient and her husband confirmed the cyclic changes to her symptomatology. Both the patient and her husband kept a symptom log over the next month and she gave consent to participate in the study.

On day 25 (of a 28 day cycle) Danielle called the clinic, complaining of severe agitation and moodiness. She was scanned the same day. Her SPECT study revealed significant increased activity in the anterior and central cingulate gyrus and increased activity in the left basal ganglia and deep left temporal lobe. Also, there was decreased activity in the prefrontal cortex and left temporal lobe. She was then scanned on day 10 of the next menstrual cycle when she was symptom free. Her follow-up scan revealed improved a calming of the cingulate, basal ganglia and temporal lobe hyperactivity and improved activity in the prefrontal cortex and temporal lobes.

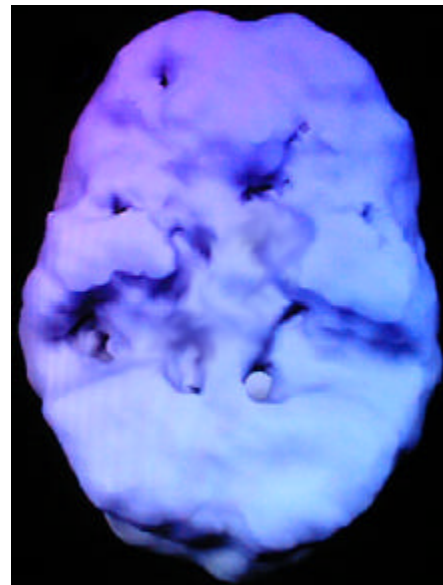
Divalproate, sertraline and fluoxetine were ineffective in treating her symptoms, but she had a positive response to lithium carbonate at a dose of 1,200 milligrams a day, with a blood level of 0.6 mcg/dl. Three years later she remains symptom free during the premenstrual period

Day 25
During Worst Time

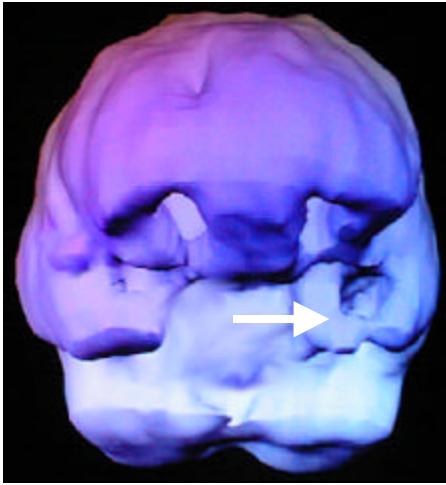


underside surface view
marked decreased prefrontal and temporal activity

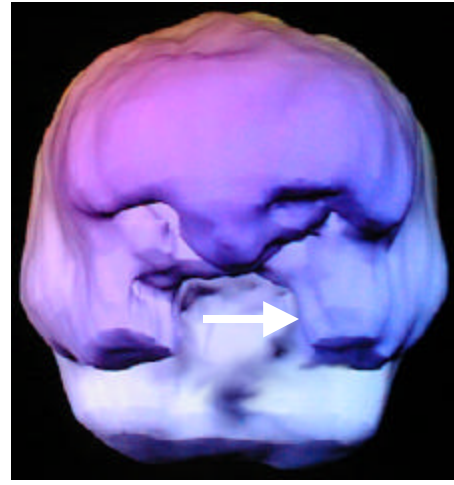
Day 10
During Best Time



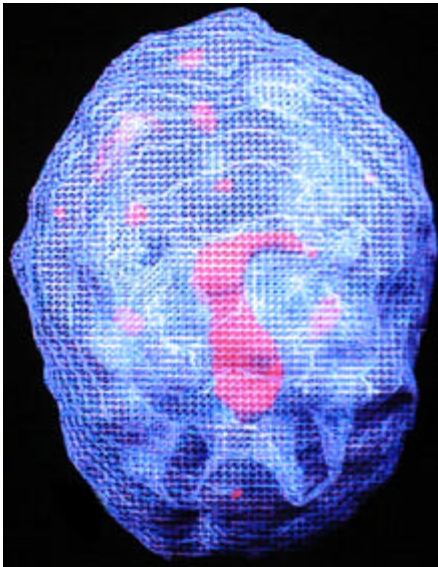
underside surface view
notice marked overall improvement



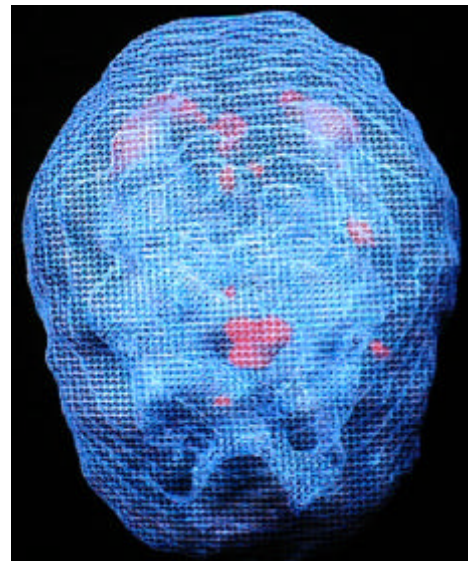
front on surface view
notice decreased prefrontal and
left temporal lobe (arrow) activity



front on surface view
notice fuller prefrontal and
left temporal lobe (arrow) activity



top down active view
notice marked increased cingulate activity



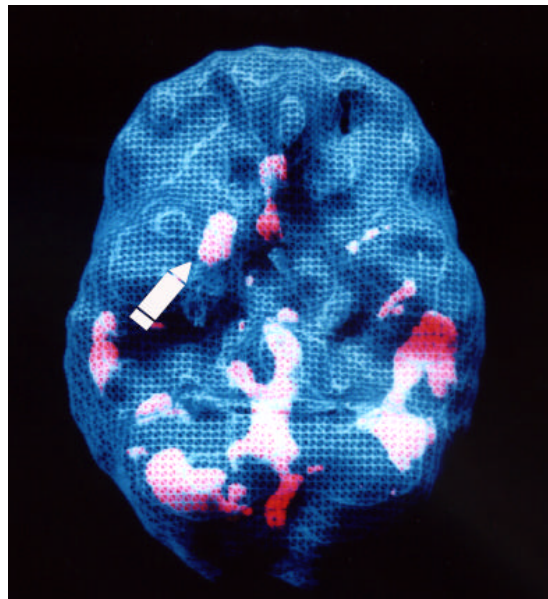
top down active view
notice calming of cingulate hyperactivity

Section 11

IMAGES OF ANXIETY

Increased basal ganglia activity is often a finding we have seen with anxiety disorders. When there is increased activity on the left side it is often associated with anxiety and irritability (expressed anxiety) and when there is increased activity on the right side there is often anxiety, social withdrawal and conflict avoidance. Increased activity in the temporal lobes has also been associated with anxiety. When there is also increased cingulate activity a person may have trouble with repetitive thoughts about his or her anxiety. Here are several examples.

Marsha, a critical care nurse, was forced into treatment by her husband. She was 36-years-old when she first began experiencing panic attacks. She was in a grocery store when all of a sudden she felt dizzy, short of breath, with a racing heart and a terrible sense of impending doom. She left her cart in the store and ran to her car where she cried for over an hour. After her first episode, the panic attacks increased in frequency to the point where she stopped going out of her house, fearing that she'd have an attack and be unable to get help. She stopped working and made her husband take the children to and from school. Her subsequent symptoms typically included shortness of breath, heart palpitations, cold hands, a terrifying sense of impending doom, sweating and negative thinking. She was opposed to any medication, because in the past her mother, in attempting to treat her own panic attacks, became addicted to Valium and was often quite mean to my patient Marsha. She did not want to see herself as being in any way like her mother. She believed that she "should" be able to control these attacks. Her husband, seeing her dysfunction only worsen, made the appointment and physically brought her to see a family counselor. The counselor taught her relaxation and how to talk back to negative thoughts, but it didn't help her. Her condition worsened and her husband brought her to see me.



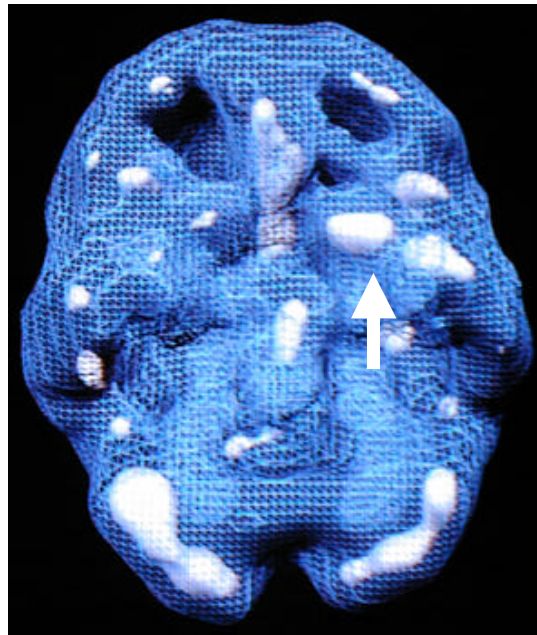
underside active view
note increased right basal ganglia activity (arrow)

Given her resistance to medication I decided to order a SPECT study to evaluate and then also be able to show her her own brain function. Her SPECT study was abnormal. It revealed marked increased focal activity in the right side of her basal ganglia. This is a very common finding in patients who have a panic disorder. Interestingly, patients who have active seizure activity also have focal areas of increased activity in their brains. My colleagues and I wonder if the basal ganglia findings are the behavioral equivalent to seizures with the intense level of emotions associated with panic attacks.

The findings on her scan convinced Marsha to try medication. I put her on Klonopin, an anti-anxiety medication that is also used for seizure control. In a short period of time she became able to go out of her house, back to work and resume her life. In addition to the medication, I taught her the group of "Basal Ganglia Prescriptions" (given later) including sophisticated biofeedback and relaxation techniques and worked with her on correcting the negative "fortune-telling thoughts. Several years later she was able to completely stop her medication and has remained "panic free."

A Case Of Post Traumatic Stress Disorder

Mark, a 50-year-old business executive, was admitted to the hospital shortly after he tried to kill himself. His wife had just started divorce proceedings against him, and he felt as though his life was falling apart. He was angry, hostile, frustrated, distrusting and chronically anxious. His co-workers felt that he was "mad all the time." He also complained of a constant headache. Mark was also a decorated Vietnam Veteran, an infantry soldier with over 100 kills. He told me that he lost his humanity in Vietnam and that the experience made him "numb."



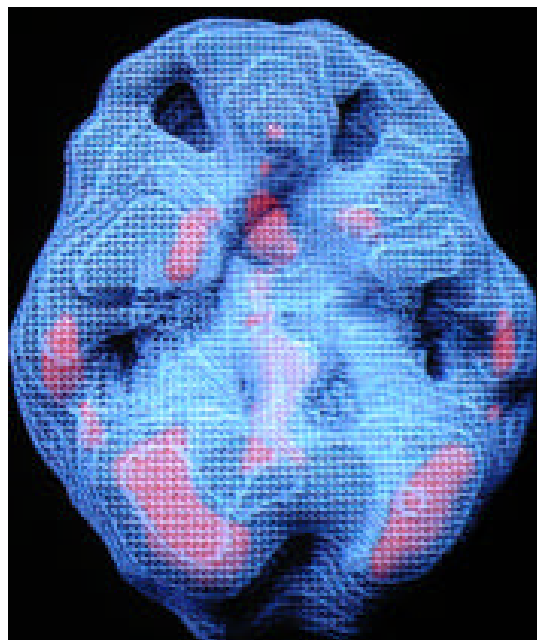
underside active view
note increased left basal ganglia activity (arrow)

In the hospital, he said that he was tormented by the memories of the past. Mark had post traumatic stress disorder (PTSD). He felt that with his wife leaving him, he had no reason to live. Due to the severity of his symptoms, along with a history of a head injury in Vietnam, I ordered a brain SPECT study. It was abnormal, showing marked increased activity in the left basal ganglion. It was the most intense activity in that part of the brain I had ever seen.

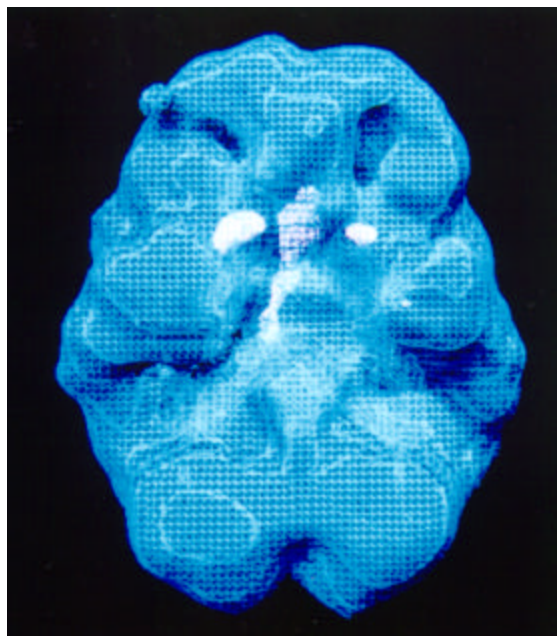
Left-sided basal ganglion findings are often seen in people who are chronically irritable or angry. Mood stabilizers, such as Lithium, Tegretol, or Depakote, are often helpful in decreasing the irritability and calming down focal “hot” areas in the brain. I placed Mark on Depakote. Almost immediately, his headaches went away and he began to feel calmer. The hospital staff noted how much calmer he was. He stopped snapping at everyone and he became more able to do the psychological work of healing from his divorce and the wounds from Vietnam.

In working with Mark, I often felt that his experiences in Vietnam had reset his basal ganglia to be constantly on the alert. Nearly everyday for 13 months of the war, he had to be “on alert” in order to avoid being shot. Through the years, he never had the chance to learn how to reset his brain back down to normal. The medication and therapy allowed him to relax, and feel, for the first time in 25 years, that he had truly left the war zone.

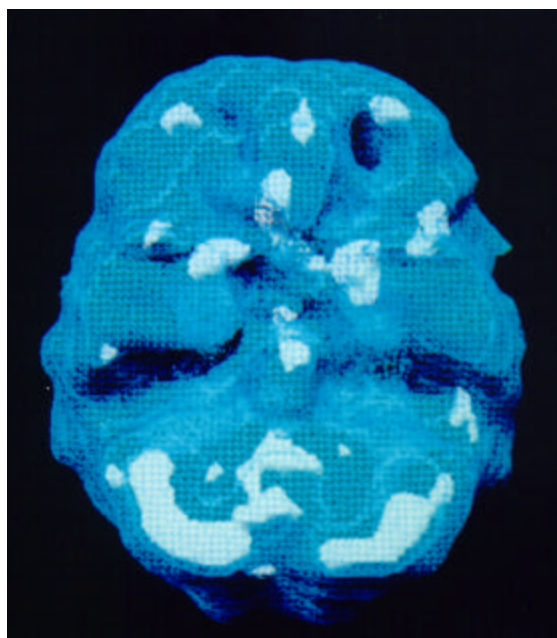
Here are several other examples.



underside active view
note increased right basal ganglia
28 year old woman with chronic anxiety, conflict avoidance



underside active view
note increased right basal ganglia
44 year old man with chronic mild anxiety, conflict avoidance



underside active view
note increased right and left basal ganglia
48 year old man with panic disorder

Section 12

IMAGES OF ATTENTION DEFICIT DISORDER

The first evidence for the brain being understimulated was introduced with the use of more advanced electroencephalograms (EEG or brainwave studies) BY Joel Lubar from the University of Tennessee. He demonstrated that when ADD children and teenagers performed a concentration task there was an increased amount of slow brain wave activity in their frontal lobes, instead of the usual increase in fast brain wave activity that was seen in the majority of the control group.

In 1990, published PET data that supported the notion of brain underactivity in the prefrontal cortex, especially in response to an intellectual challenge. Data from my own work with brain SPECT imaging drew the same conclusions. At rest most ADD people have normal activity in their brain. When they perform a concentration task, however, they experience decreased activity in the prefrontal cortex, rather than the expected increased activity that is seen in a normal control group.

Tied to the decreased prefrontal cortex findings are the studies that indicate that ADD is has a large genetic contribution, involving dopamine availability in the brain. A significant amount of dopamine is produced in the basal ganglia (large, structures deep within the brain). Stimulant medications work by enhancing dopamine availability in this part of the brain. Studies have demonstrated that the basal ganglia is smaller in people with ADD. The basal ganglia have a significant number of nerve tracks that go through the limbic system to the prefrontal cortex. It appears that when there is not enough dopamine available in the basal ganglia then there is not enough 'fuel' to drive the frontal lobes when they need to activate with concentration.

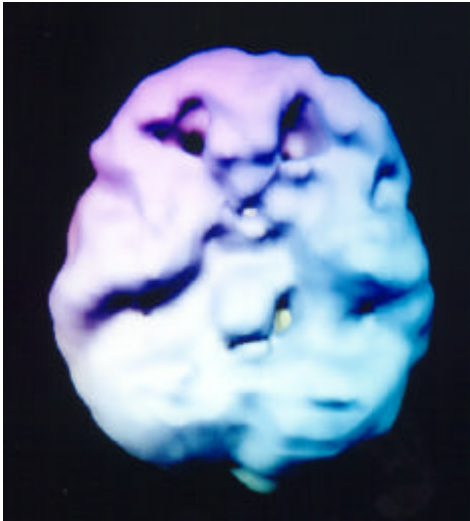
Beside the genetic contribution to ADD, maternal alcohol or drug use, birth trauma, jaundice, brain infections and head trauma (sometimes even minor ones, especially to the left prefrontal cortex) can play a causative role.

Subtypes of ADD

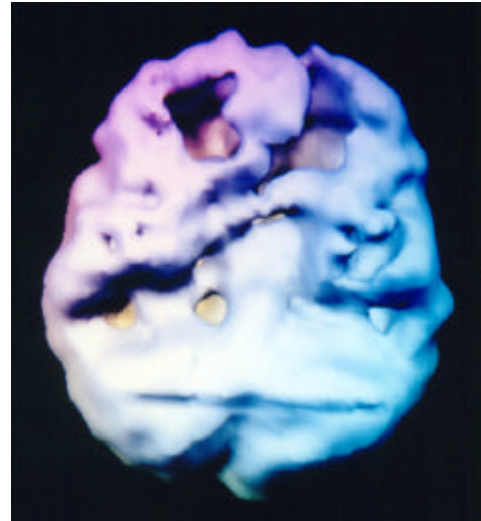
It is essential to note that ADD is a developmental disorder diagnosed through clinical history over a prolonged period of time. Brain imaging is not necessary to make the diagnosis of ADD, although it may be helpful in certain complicated cases. Based on my brain imaging experience I have seen 5 clinical subtypes of ADD:

1. AD/HD, combined type with both symptoms of inattention and hyperactivity-impulsivity. Brain SPECT imaging typically shows decreased activity in the basal ganglia and prefrontal cortex during a concentration task. This subtype of ADD typically responds best to psychostimulant medication.

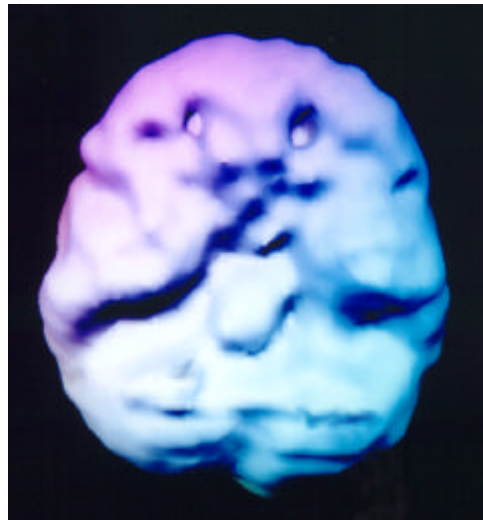
Rest, Concentration & Concentration with Medication



undersurface view, rest
mild decrease prefrontal area



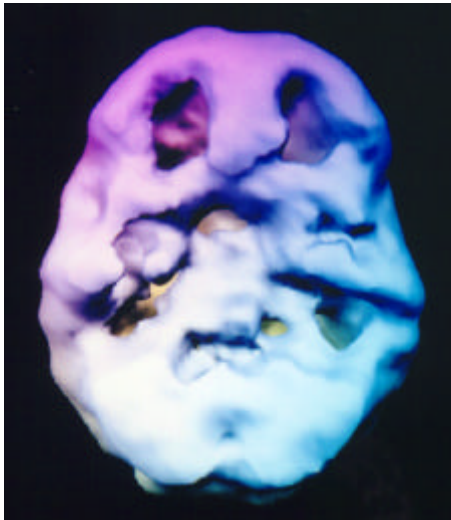
undersurface view, concentration
marked decrease prefrontal cortex
and left temporal lobe



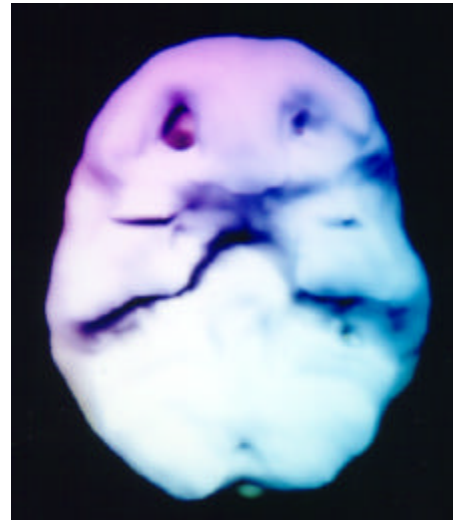
undersurface view, w/Adderall
overall marked improved activity

2. AD/HD, primarily inattentive subtype with symptoms of inattention and also chronic boredom, decreased motivation, internal preoccupation and low energy. Brain SPECT imaging typically shows decreased activity in the basal ganglia and dorsal lateral prefrontal cortex during a concentration task. This subtype of ADD also typically responds best to psychostimulant medication.

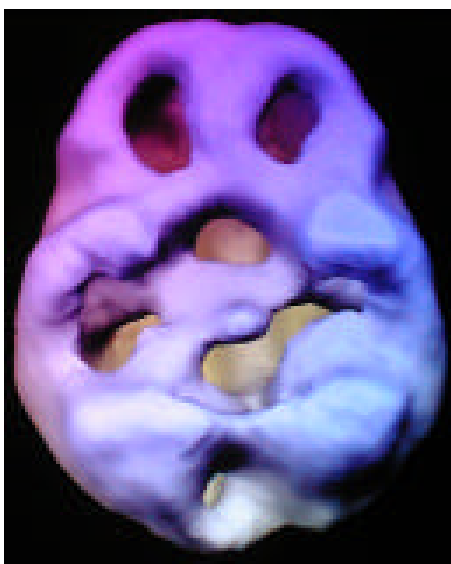
Before & After Treatment with Ritalin & Adderall



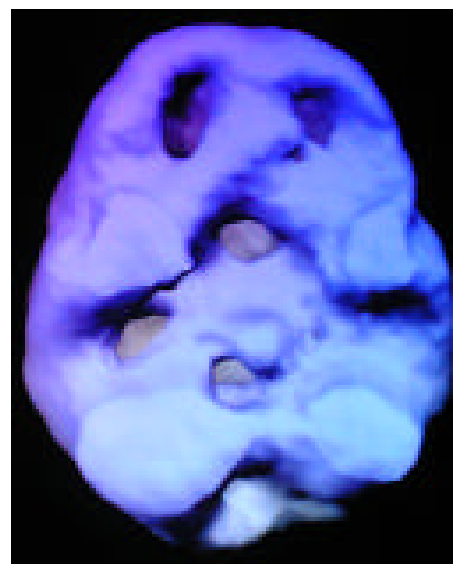
undersurface view, NO MEDS
poor prefrontal and
temporal lobe activity



undersurface view, with Adderall
marked overall improvement

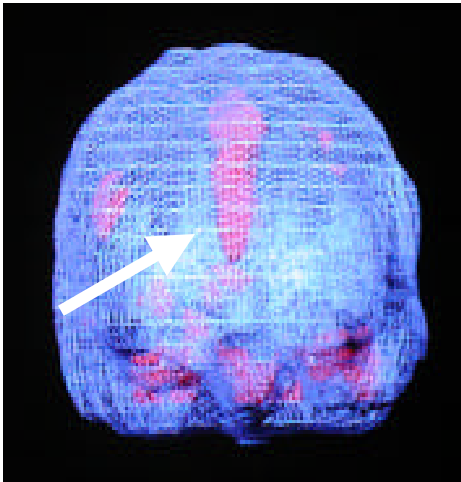


undersurface view, NO MEDS
overall severe decreased activity

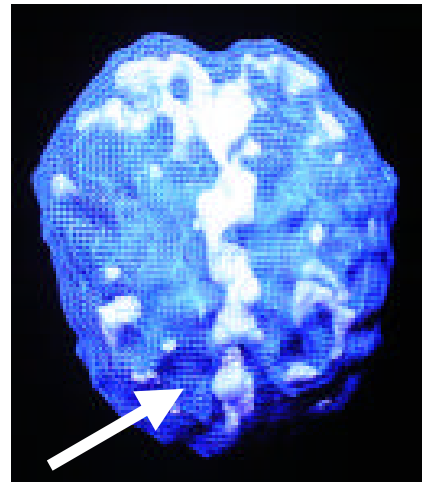


undersurface view, w/Ritalin
overall marked improved activity

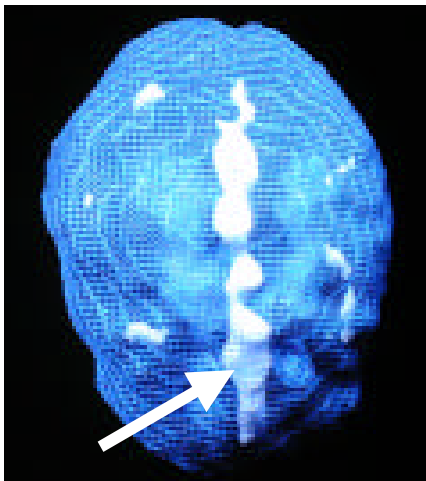
3. Overfocused ADD, with symptoms of trouble shifting attention, cognitive inflexibility, difficulty with transitions, excessive worrying, and oppositional and argumentative behavior. There are often also symptoms of inattention and hyperactivity-impulsivity. Brain SPECT imaging typically shows increased activity in the anterior cingulate gyrus and decreased prefrontal cortex activity. This subtype typically responds best to medications that enhance both serotonin and dopamine availability in the brain, such as venlafaxine or a combination of an SSRI (such as fluoxetine or sertraline) and a psychostimulant.



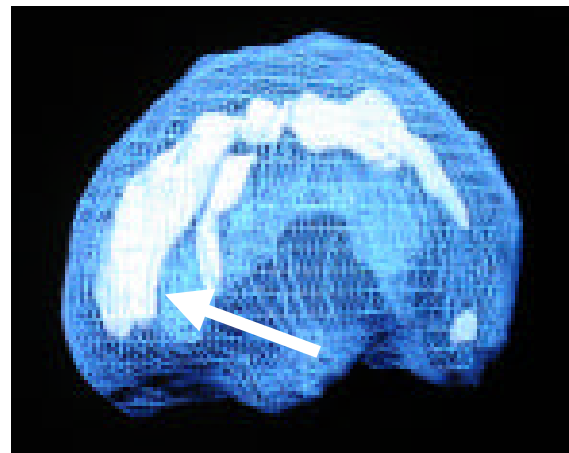
front on active view
increased cingulate activity



active top down view
increased cingulate activity

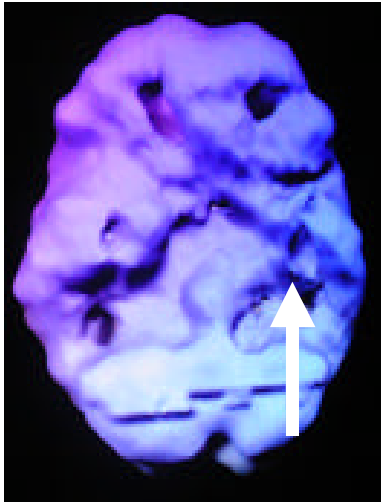


top down active view
increased cingulate activity

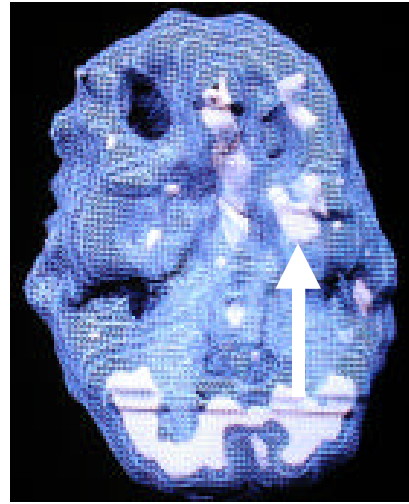


active side view
increased cingulate activity

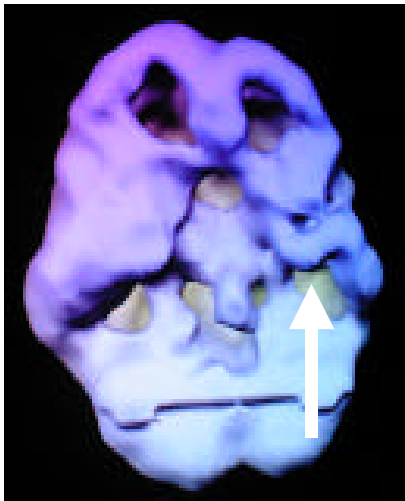4. Temporal lobe ADD, with symptoms of inattention and/or hyperactivity-impulsivity and mood instability, aggression, mild paranoia, anxiety with little provocation, atypical headaches or abdominal pain, visual or auditory illusions, and learning problems (especially reading and auditory processing). Brain SPECT imaging typically shows decreased or increased activity in the temporal lobes with decreased prefrontal cortex activity. Aggression tends to be more common with left temporal lobe abnormalities. This subtype typically responds best to anticonvulsant medications (such as gabapentin, divalproate, or carbamazepine and a psychostimulant).



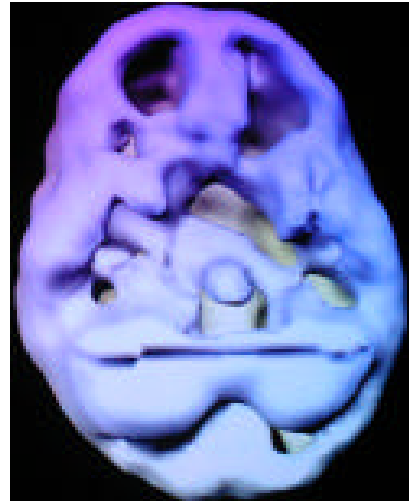
undersurface view
decreased left temporal lobe activity



underside active view
increased left temporal lobe activity

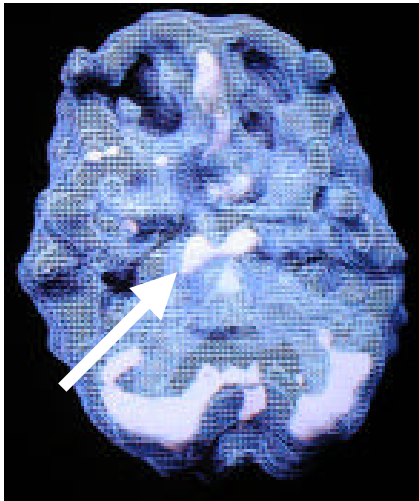


undersurface view
marked decreased left
temporal lobe activity

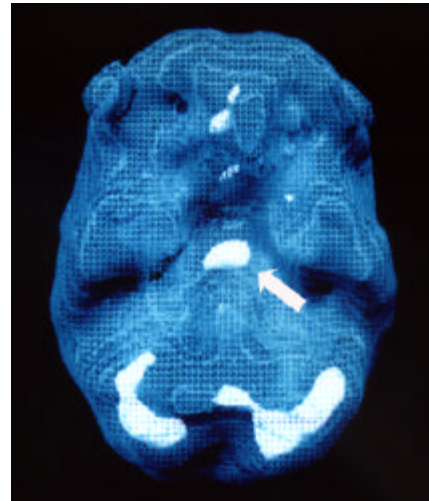


undersurface view
marked decreased temporal
and prefrontal cortex bilaterally

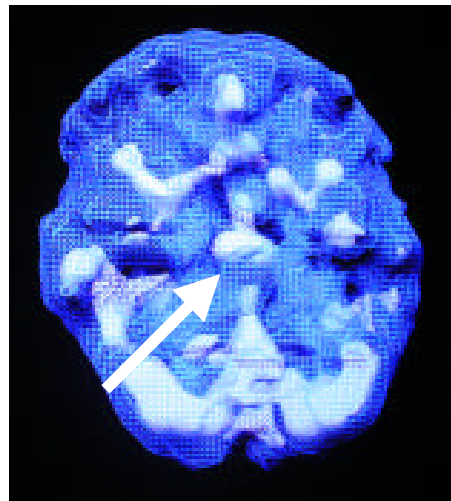
5. Limbic ADD, with symptoms of inattention and/or hyperactivity-impulsivity and negativity, depression, sleep problems, low energy, low self-esteem, social isolation, decreased motivation and irritability. Brain SPECT imaging typically shows increased central limbic system activity and decreased prefrontal cortex activity. This subtype typically responds best to stimulating antidepressants such as buprion or imipramine, or venlafaxine if obsessive symptoms are present.



underside active view
increased limbic activity

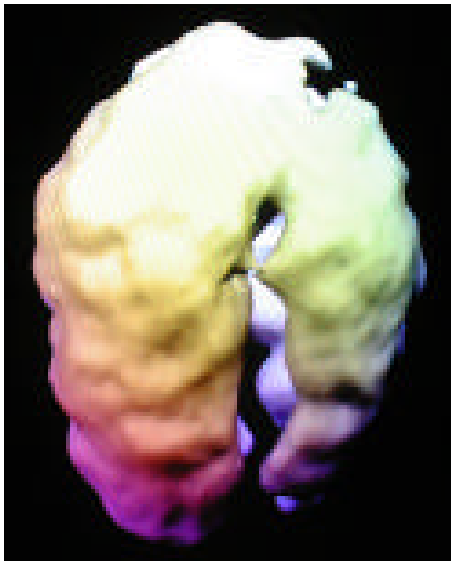


underside active view
increased limbic activity



underside active view
marked increased limbic, basal ganglia and cingulate activity

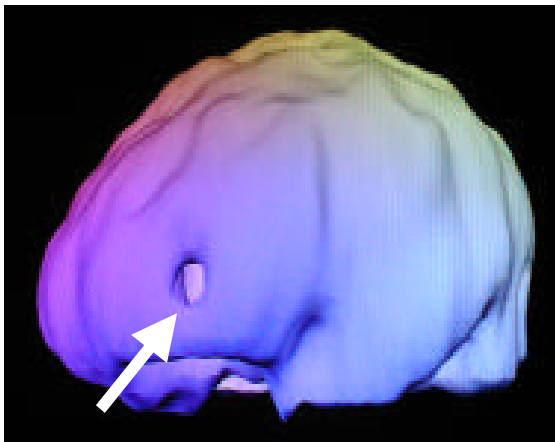
6. Trauma Induced ADD, especially to the left dorsolateral prefrontal cortex. The symptoms come on or intensify in the year after a head injury. The ADD symptoms may respond to psychostimulant medication. If irritability results secondary to psychostimulant medication the addition of a low dose anticonvulsant may be helpful.



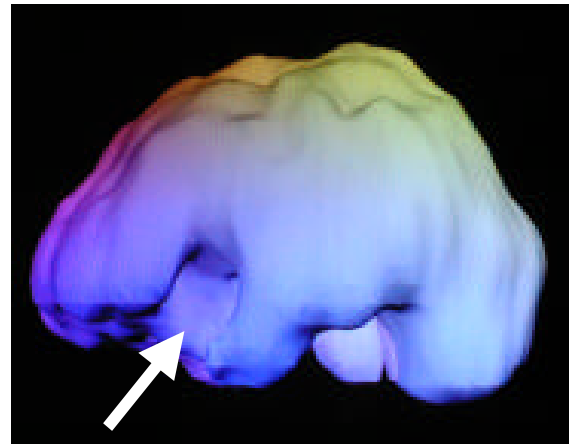
top down surface view
marked decreased left frontal
prefrontal and occipital lobes



side surface view
marked decreased left prefrontal
and anterior temporal region

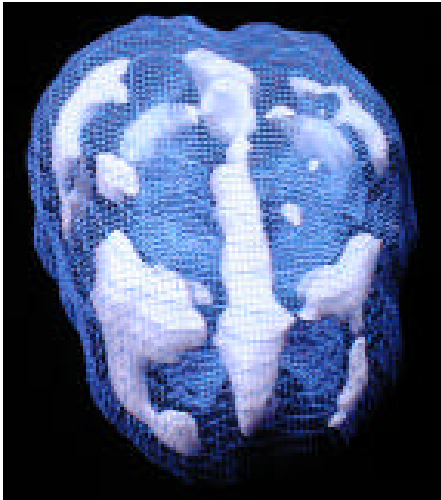


side surface view
decreased left prefrontal cortex

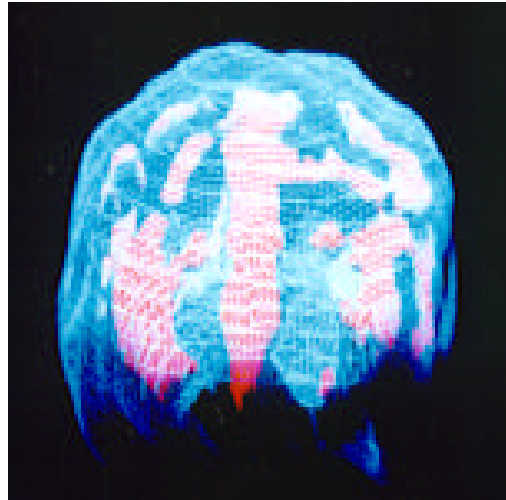


side surface view
decreased left prefrontal and
temporal lobe activity

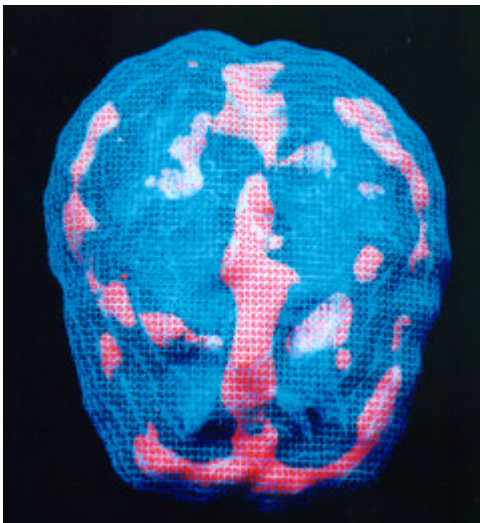
7. Ring of Fire ADD – many of the children and teenagers who present with symptoms of ADD have the “ring of fire” pattern on SPECT. They often do not respond to psychostimulant medication and in many cases are made worse by them. They tend to improve with either anticonvulsant medications, like Depakote or Neurontin, or the new, novel antipsychotic medications such as Risperdal or Zyprexa. The symptoms of this pattern tend to be severe oppositional behavior, distractibility, irritability and temper problems and mood swings. We think it may represent an early bipolar pattern.



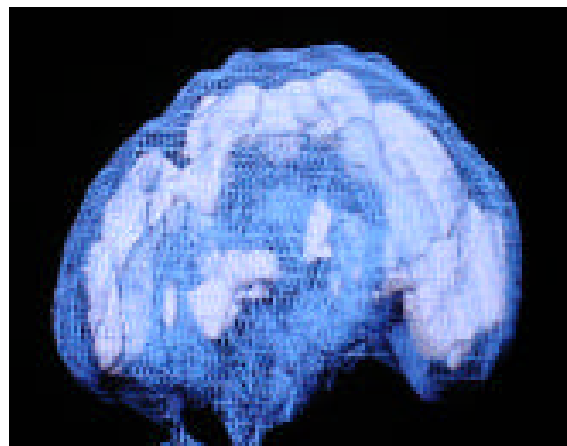
top down active view
increased activity in the cingulate,
lateral parietal, frontal and temporal lobes



active front on view
increased activity in the cingulate,
lateral parietal, frontal and temporal lobes



top down active view
increased activity in the cingulate,
lateral parietal, frontal and temporal lobes

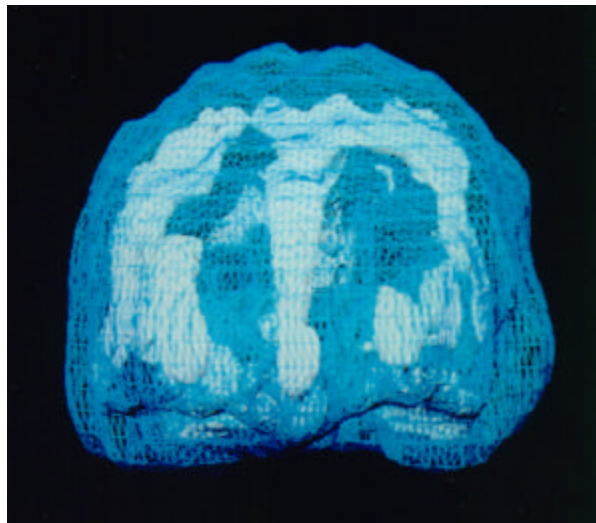


left side active view
increased activity in the cingulate,
lateral parietal, frontal and temporal lobes

Section 13

IMAGES OF OBSESSIVE COMPULSIVE SPECTRUM DISORDERS

There are a number of SPECT studies that report hyperfrontality (increased right and left anterior prefrontal cortex activity and increased anterior cingulate gyrus activity) and increased basal ganglia activity in obsessive compulsive disorder. Of interest, hyperactivity in the anterior cingulate gyrus has also been noticed in oppositional defiant disorder and violence. The anterior cingulate gyrus, which is heavily innervated by serotonergic fibers, has been postulated as being involved with shifting attention and cognitive flexibility, deficient in all of these disorders. Treatment with serotonergic antidepressants such as fluoxetine and clomipramine decrease the hyperactivity in these areas.



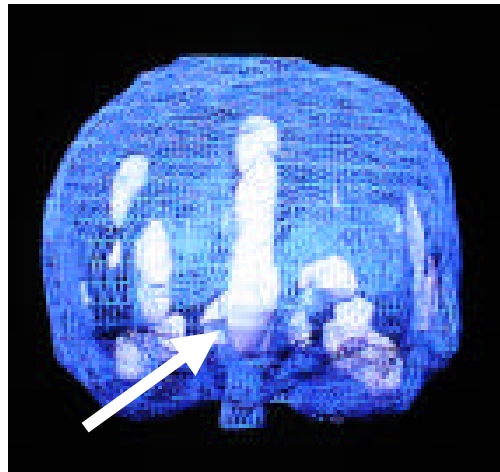
active front-on view

heavy increased cingulate activity and right and left anterior lateral prefrontal cortex activity (together termed hyperfrontality).

OCD

On the outside, Gail was normal. She went to work every day, she was married to her high school sweetheart, and she had two small children. On the inside, Gail felt like a mess. Her husband was ready to leave her and her children were often withdrawn and upset. Gail was distant from her family and locked into the private hell of obsessive compulsive disorder. She cleaned her house for hours every night after work. She screamed at her husband and children when anything was out of place. She would become especially hysterical if she saw a piece of hair on the floor, and she was often at the sink washing her hands. She also made her husband and children wash their hands more than ten times a day. She stopped making love to her husband because she couldn't stand the feeling of being messy.

On the verge of divorce, Gail and her husband came to see me. At first, her husband was very skeptical about the biological nature of her illness. Gail's brain SPECT study showed marked increased activity in the cingulate system, demonstrating that she really did have trouble shifting her attention.

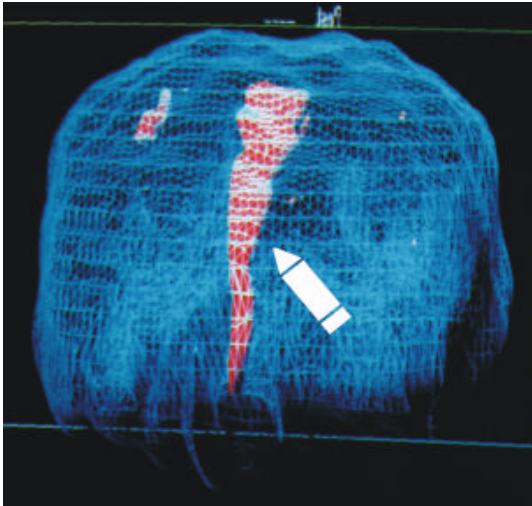


active front-on view
heavy increased cingulate activity

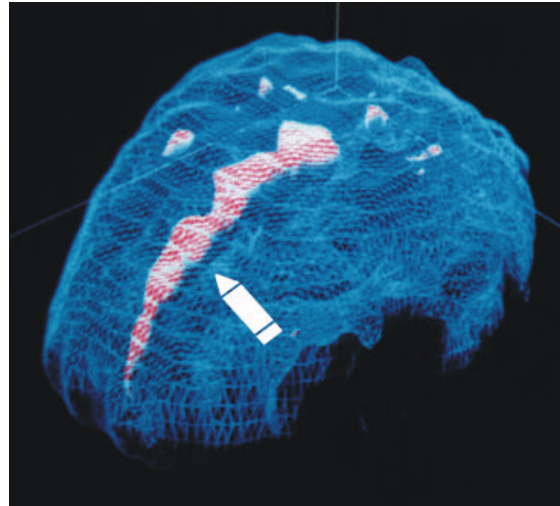
With this information, I placed Gail on Zoloft. Within six weeks, she had significantly relaxed, her ritualistic behavior had diminished and she stopped making her kids wash their hands every time they turned around. Her husband couldn't believe the change. Gail was more like the woman he married.

ODD – Oppositional Defiant Disorder

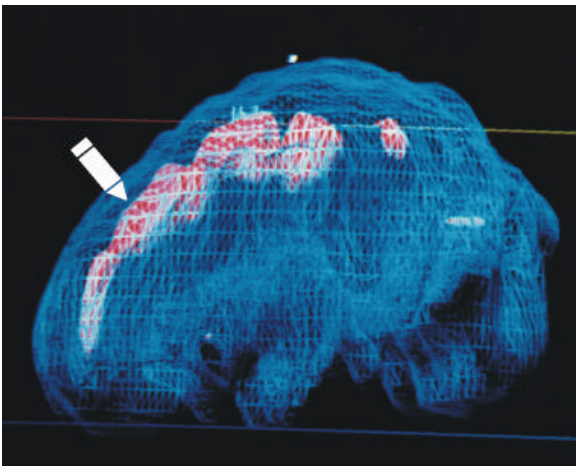
13 year old boy with severe oppositional defiant disorder



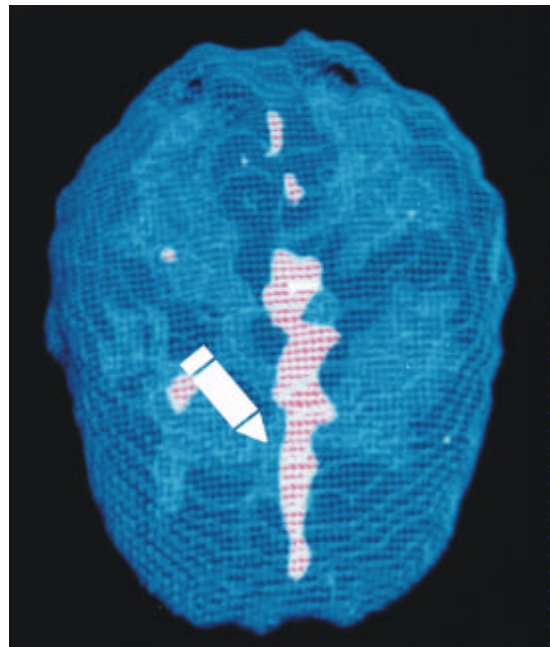
front-on active view



left top-side active view

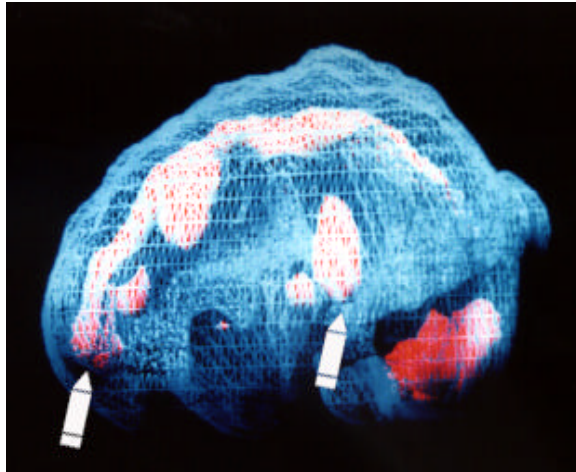


left side active view



top down active view


Road Rage



side active view

increased cingulate and left temporal lobe activity

28 year old female who has become aggressive while driving on many occasions.

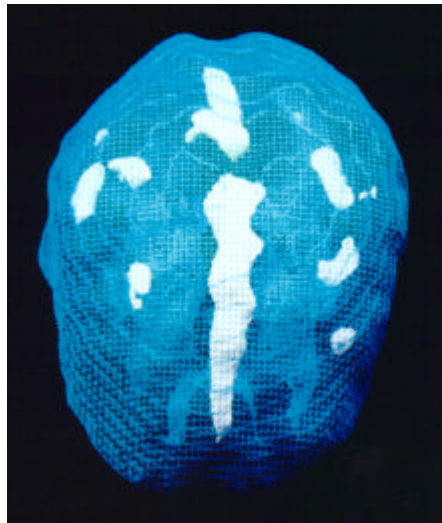


side active view

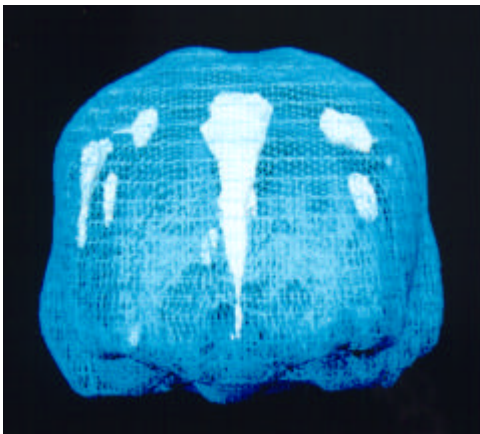
marked increased cingulate and left lateral temporal lobe activity

37 year old male attorney who, on several occasions, chased other drivers who had cut him off and on two occasions got out of the car and bashed their windows in with a baseball bat he kept in the car. After the second incident, he came to see me. He said, "If I don't get help for this I'm sure I'll end up in jail." His cingulate gyrus was markedly overactive, causing him to get locked into the negative thoughts and subsequently be less able to control his frustration. His SPECT scan shows: marked increased activity in the cingulate gyrus and left temporal lobe (arrows), which correlates with irritability and overfocus issues.

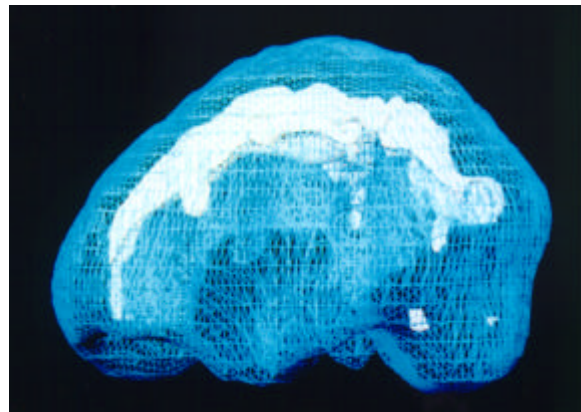
Pathological Gambling



top down active view



front on active view

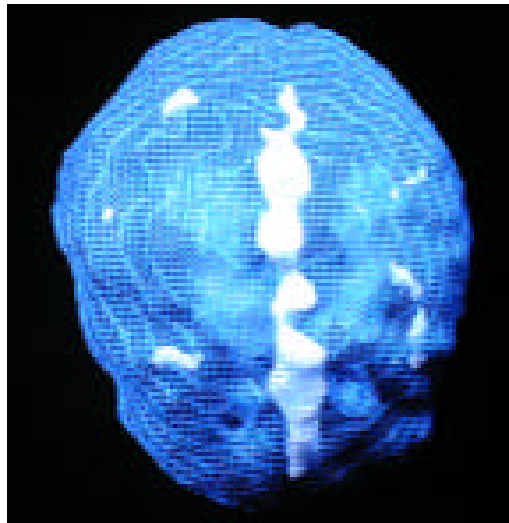


side active view

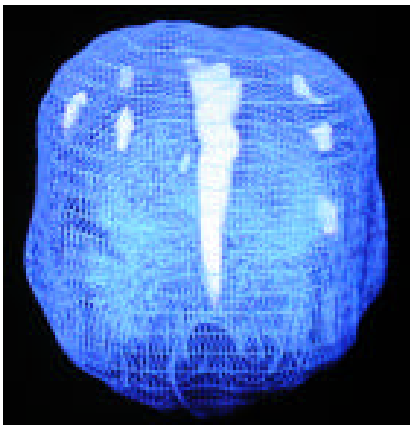
marked increased cingulate activity

Adam came to our office when his wife left him. His gambling had gotten out of control. In the past few years he began neglecting his business spending more of his time at the racetrack and driving back and forth to the casinos in Reno and Lake Tahoe. "I feel compelled to gamble. I know it is ruining my life, but it seems I have to place a bet or the tension just builds and builds. It is all I think about!" Adam's SPECT study showed heavy increased cingulate activity. Explaining the cingulate system to Adam was helpful. He could identify many people in his family who had problems shifting attention. You should see our family gatherings," he told me, "someone is always mad at someone else. People in my family can hold grudges for years and years." In addition to going to Gamblers Anonymous and being seen in psychotherapy I prescribed a small dose of Prozac for him to help him shift away from the obsessive thoughts about gambling. Eventually, he was able to reconnect with his wife and rebuild his business.

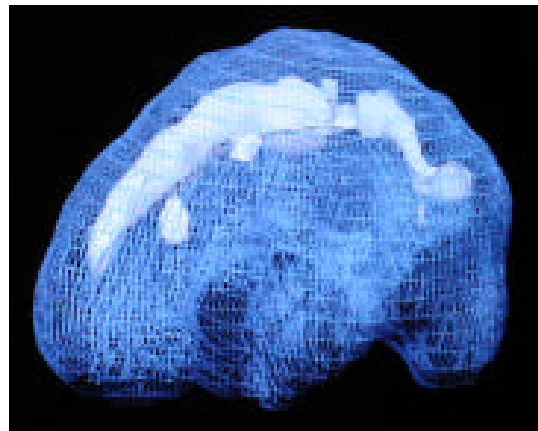
Chronic Pain



top down active view



front on active view



side active view

marked increased cingulate activity

Stewart, a 40-year-old roofer, hurt his back ten years ago when he fell off a roof. He underwent six back operations but remained in constant pain. He was essentially bedridden and about to lose his family because all he could think about was the pain. The threat of losing his family catalyzed him to get a psychiatric evaluation. His SPECT revealed marked overactivity in the cingulate system. He was placed on Anafranil 200 mg. a day. After 5 weeks, he reported that his back still hurt, but he was much less focused on the pain. He was able to get out of bed and start back to school. Other researchers have also reported several cases of intractable pain that were also responsive to treatment with anti-obsessive medications.

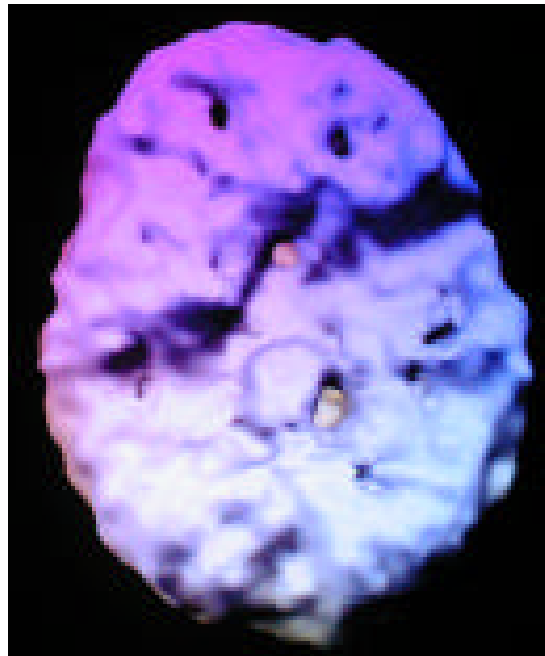
Section 14

IMAGES OF VIOLENCE

SPECT can be helpful in understanding and treating aggressive behavior. I have found a consistent triad of SPECT findings common in children, teenagers and adults who exhibit aggressive behavior. These findings include:

- abnormalities (either increased or decreased activity) in the left temporal lobe, often the seat of aggressive thoughts
- increased activity in the anterior cingulate gyrus, which often causes problems with repetitive thoughts and shifting attention (a person may get stuck on the aggressive thoughts that are present) and
- decreased activity in the prefrontal cortex, leading to poor internal supervision.

When these three findings are present it is often helpful to intervene with anticonvulsant medication to stabilize temporal lobe abnormalities and decrease violent thoughts, a serotonergic agent to help decrease anterior cingulate activity and improve cognitive flexibility, and sometimes a psychostimulant to activate prefrontal cortex activity and enhance impulse control.

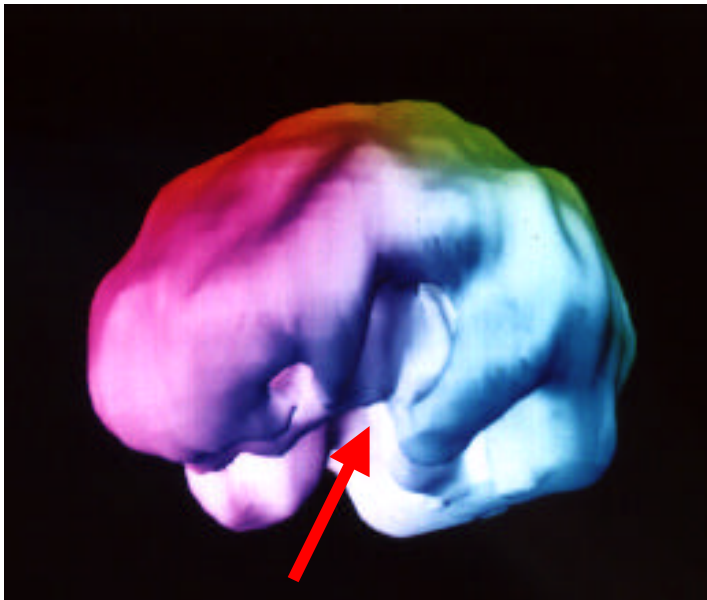

underside surface view

arachnoid cyst occupying the space of the left temporal lobe in a violent 9 year old boy

John

John, a right-handed 79-year-old contractor, had a longstanding history of alcohol abuse and violent behavior. He had frequently physically abused his wife over 40 years of marriage and had been abusive to the children when they were living at home. Almost all of the abuse occurred when he was intoxicated. At age 79, John underwent open-heart surgery. After the surgery he had a psychotic episode, lasting 10 days. His doctor ordered a SPECT study as part of his evaluation. The study showed marked decreased activity in the left outside frontal-temporal region, a finding most likely due to a past head injury. When the doctor asked John if he had ever had any significant head injuries, John told him about a time when he was 20-years-old. While driving an old milk truck, that was missing its side rear mirror, he put his head out of the window to look behind him. His head struck a pole, knocking him unconscious for several hours. After the head injury he had more problems with his temper and memory. There was a family history of alcohol abuse in 4 of his 5 brothers. None of his brothers had problems with aggressive behavior.



left lateral surface view

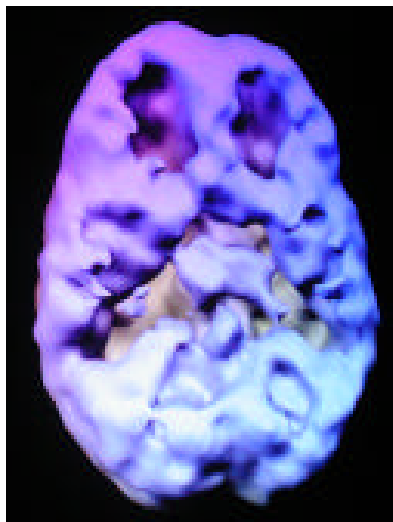
note marked area of decreased activity in the left frontal and temporal region

Given the location of the brain abnormalities (left frontal-temporal dysfunction) he was more likely to exhibit violent behavior. The alcohol abuse, which did not elicit violent behavior in his brothers, did in him. Knowing this information earlier might well have been useful in obtaining help for his problems.

Bradley

Bradley was diagnosed with attention deficit/hyperactivity disorder (ADHD) and left temporal lobe dysfunction (diagnosed by EEG) at the age of 14. Before then (from grades 1-8) he had been expelled from 11 schools for fighting, frequently cut school and had already started drinking alcohol and using marijuana. He had a positive response to Ritalin. He improved three grade levels of reading within the next year, attended school regularly and had no aggressive outbursts. However, Bradley had a negative emotional response to taking medication. Two years after starting his medication he decided to stop it on his own without telling anyone. His anger escalated. One night his uncle came to his home and asked Bradley to help him “rob some bitches.” Bradley went with his uncle who forced a woman into her car, made her go to her ATM and withdraw money. The uncle and Bradley then raped the woman twice. He was apprehended two weeks later and charged with kidnapping, robbery and raped.


As the psychiatric forensic consultant I ordered a series of brain SPECT studies: the rest study showed mild decreased activity in the left prefrontal cortex and the left temporal lobe. While performing a concentration task there was marked suppression of the prefrontal cortex, a finding commonly found in attention deficit hyperactivity disorder and both temporal lobes. A third scan was done 1 hour after taking 15 mg. of methylphenidate. This scan showed marked activation in the prefrontal cortex and both temporal lobes, although there was still some mild deactivation in the left temporal lobe. After understanding the history and reviewing the scan data it was apparent that Bradley already had a vulnerable brain that was consistent with long term behavioral and academic difficulties. His substance use may have further suppressed an already underactive prefrontal cortex and temporal lobe diminishing executive abilities and unleashing aggressive tendencies. It is possible that with an explanation of the underlying metabolic problems and brief psychotherapy on the emotional issues surrounding the need to take medication this serious problem might have been averted.



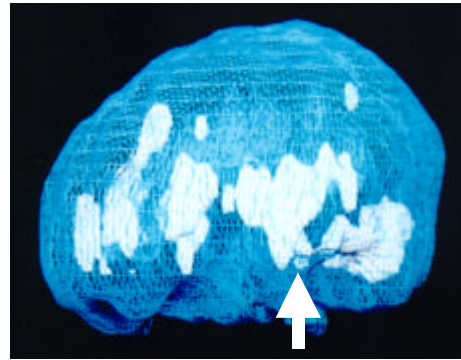
*underside surface view, concentration study, no medication
marked decreased prefrontal and temporal lobe activity*

Rusty

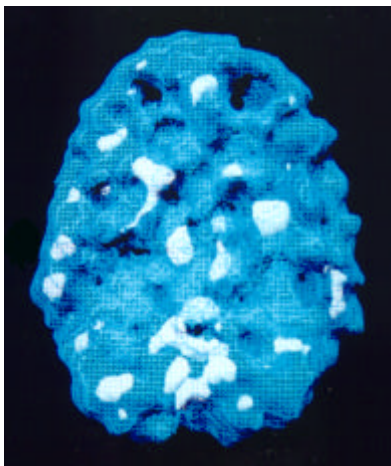
Twenty-eight-year-old Rusty had a severe methamphetamine problem. He was unable to keep steady work, he was involved in a physically abusive relationship with his girlfriend (arrested four times for assault and battery), he was mean to his parents even though they tried to help him. He failed five drug treatment programs. Since Rusty's mom scheduled his SPECT study he was unaware of it until the morning of the scan. He showed up loaded with a gram of methamphetamine from the night before. Rusty told me about his drug abuse. I decided to scan Rusty that morning with the effects of the methamphetamine still in his system and then a week later off all drugs. When Rusty was under the influence of high dose methamphetamine his brain looked suppressed in activity. A week later, however, off all drugs, he had a terribly hot or overactive left temporal lobe, probably causing his problems with violent behavior. Rusty was likely self-medicating an underlying temporal lobe problem with high dose methamphetamine. Given this finding, I put Rusty on Tegretol (an anti-seizure medication which stabilizes activity in the temporal lobes). Within 2 weeks Rusty felt better than he had in years. He was calmer, his temper was under control and for the first time in his life he was able to remain gainfully employed. An additional benefit of the scan was that I showed Rusty the serious damage he was doing to his brain by abusing the methamphetamines. Even though the drugs helped his temporal lobe problem, they were clearly toxic to his brain.



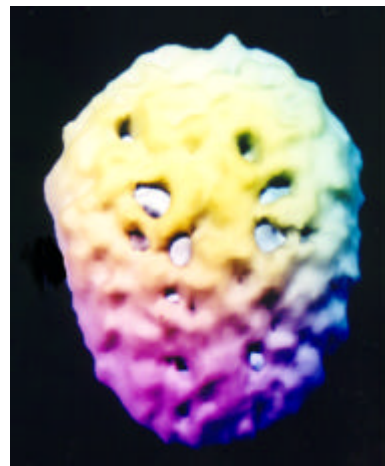
active side view
on high dose methamphetamine



active side view
off methamphetamine



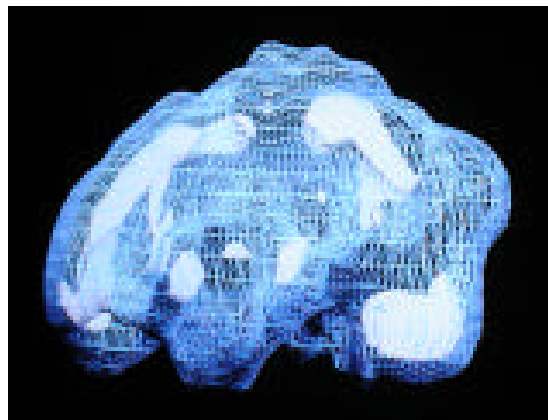
underside active view
notice hot area deep left temporal lobe



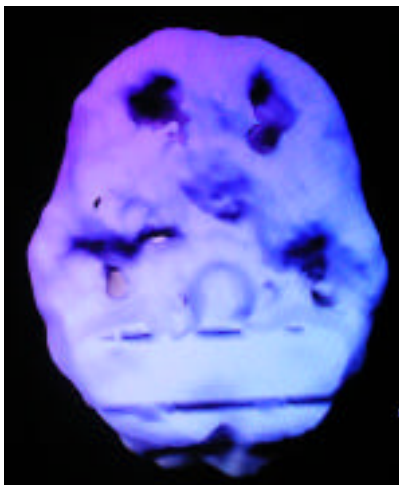
top-down surface view
notice multiple holes across cortex

Jose

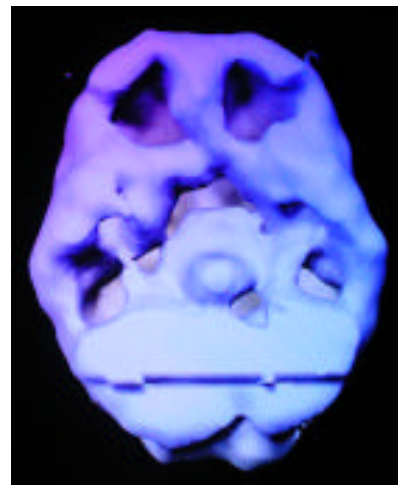
Jose, a 16-year-old gang member, was arrested after he and another gang member beat another teenager nearly to death. They were charged with attempted murder. Their gang claimed the color red. One evening, when they were in an intoxicated state (from both alcohol and heavy marijuana usage), they approached a boy who was wearing a red sweater walking his dog across the street. They asked him, “What colors do you bang?” (asking him about his gang affiliation). When the boy said he did not know what they were talking about Jose replied, “Wrong answer,” and the two gang boys started to physically attack the boy, hitting and kicking him repeatedly until he was unconscious. The public defender ordered neuropsychological testing on Jose which found frontal lobe dysfunction and evidence of ADHD, depression and learning disabilities. The psychologist suggested a resting and concentration SPECT series for independent verification. The SPECT series was significantly abnormal. Both studies showed *marked increased activity in the cingulate gyrus*, consistent with problems shifting attention. At rest, his SPECT also showed mildly suppressed prefrontal cortex activity. While doing a concentration task there was also marked suppression of the prefrontal cortex and both temporal lobes, consistent with ADHD, learning disabilities and aggressive tendencies.



left side active view
marked increased cingulate



at rest
mild decreased pfc activity

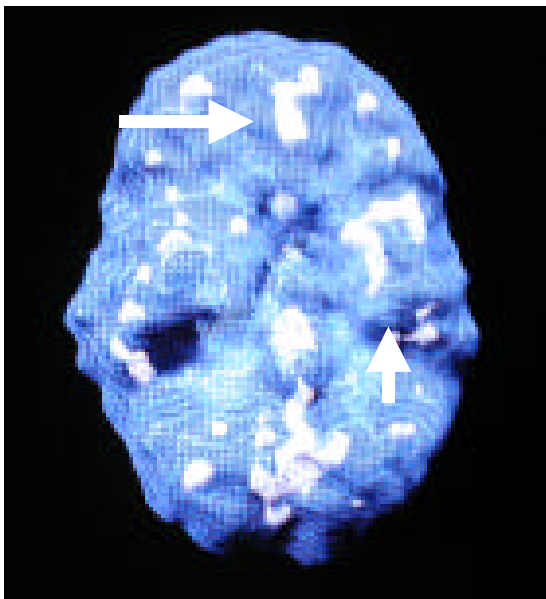


during concentration
marked decreased pfc and temporal lobe activity


Paul

Paul, a 28 year old gardener, came to my clinic for work-related problems. He had increasingly intense feelings of rage toward his boss. Paul said that his boss was prejudiced against him because he was Hispanic. He frequently thought about killing his boss. He reported that only the thought of his wife and small daughter prevented him from doing physical harm to his boss. He needed to maintain his job in order to support his family. Paul could not get the anger toward his boss out of his head. He reported that since childhood he had many explosive outbursts. He saw himself as someday being on the top of a tower shooting down at people. His anger was diffuse. He described himself as having an extremely short fuse, especially while driving. At the age of 7 he ran full speed into a metal basketball pole and was unconscious for several minutes. Paul had no evidence of a psychotic disorder or a significant depression, although he did complain of short periods of confusion, fear for no reason and episodes of *deja vu*. His EEG was within normal limits. A brain SPECT study was obtained in order to further evaluate any underlying brain abnormalities that might have been contributing to his difficulties.

Paul's brain SPECT study was significantly abnormal. It revealed normal activity in the prefrontal cortex at rest that worsened when he tried to concentrate (problems with impulsivity). There was also moderate marked increased uptake in the deep aspects of the left temporal lobe (short fuse) and his cingulate gyrus (stuck on thoughts). Because of the clinical picture and information from the brain SPECT study Paul was placed on the anticonvulsant Tegretol at therapeutic levels, along with Prozac several weeks later. After six weeks, he reported that he noted a sense of increased inner control and inner peace. His periods of confusion, *deja vu* and fearfulness diminished. His anger outbursts decreased and he was able to go to work at a new job.



underside active view



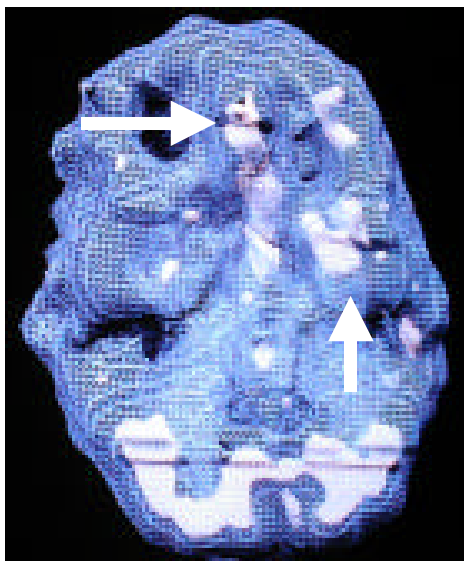
left side active view

note marked increased activity in the left temporal lobe and cingulate (arrows)

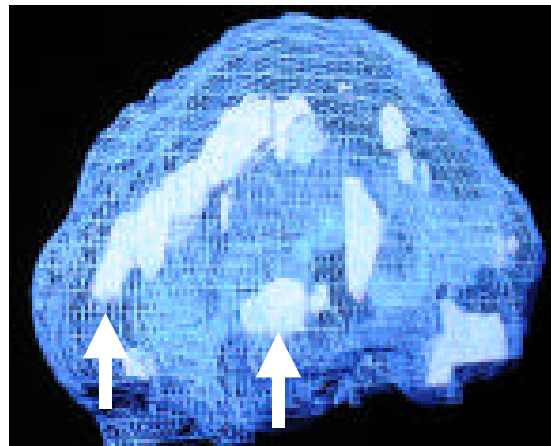
Steven

Steven, a 39-year-old radio station engineer, was admitted to the hospital for suicidal thoughts. He was recently separated from his wife of eight years. During their relationship there had been mutual physical spousal abuse for which he had spent some time in jail. Steven also complained of having a very "short fuse." He found himself frequently yelling at other drivers on the road and was easily upset at work. On admission he was tearful, had problems sleeping and poor concentration. He was depressed and experienced with suicidal thoughts. He reported short periods of confusion, periods of feeling intense rage with little provocation, and episodic periods where he would see shadows out of the corners of his eyes. His EEG was within normal limits.

Steven's brain SPECT study revealed marked increased uptake in the deeper aspects of the left temporal lobe and marked increased activity in the cingulate gyrus.



underside active view



left side active view

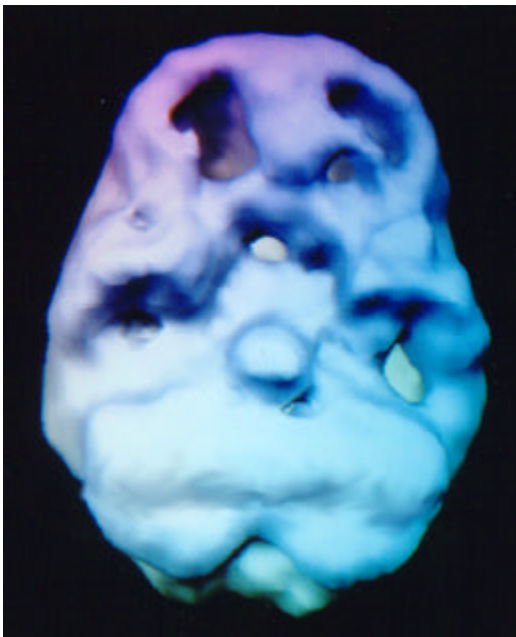
note marked increased activity left temporal lobe and cingulate (arrows)

With the clinical picture and information from the brain SPECT it was decided to start Steven on an anticonvulsant in addition to an antidepressant. He was placed on Tegretol at therapeutic levels along with Prozac. Even though he continued to feel sad about the break up of his marriage, he felt calmer, in better self-control and his suicidal thoughts abated. He did report that he wished he had known about the dysfunction in his temporal lobe years earlier. He felt it might have changed the outcome of his marriage.

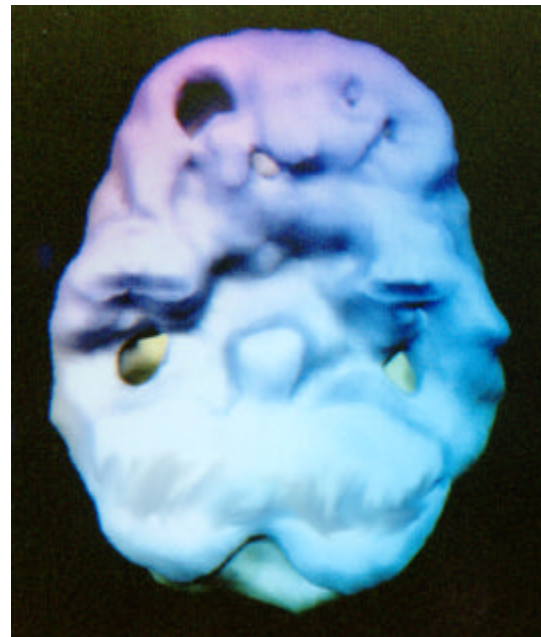
Jody

In December 1996 Jody Gordon walked into the McDonald's in Vallejo, California where he had been fired from his job the year before. He carried two guns and a knife. Three teenage girls, employees of McDonald's, were sitting at a table having a snack after a meeting they had been called into work for. Jody asked the manager for his job back. When the manager refused Jody walked over to the girls and started shooting. He killed one of the girls and wounded the other two.

As part of his defense I was asked to perform a brain SPECT study to evaluate his brain function. He had one of the most severe decreases in prefrontal cortex function I had ever seen. I then had him come back for a second scan and gave him 20 milligrams of Adderall to see if I could enhance the severe prefrontal hypoperfusion. To my amazement, the Adderall significantly enhanced the activity in his brain, especially in his prefrontal cortex. I wondered if he would have committed this terrible crime if he had more access to the part of his brain involved in decision making.

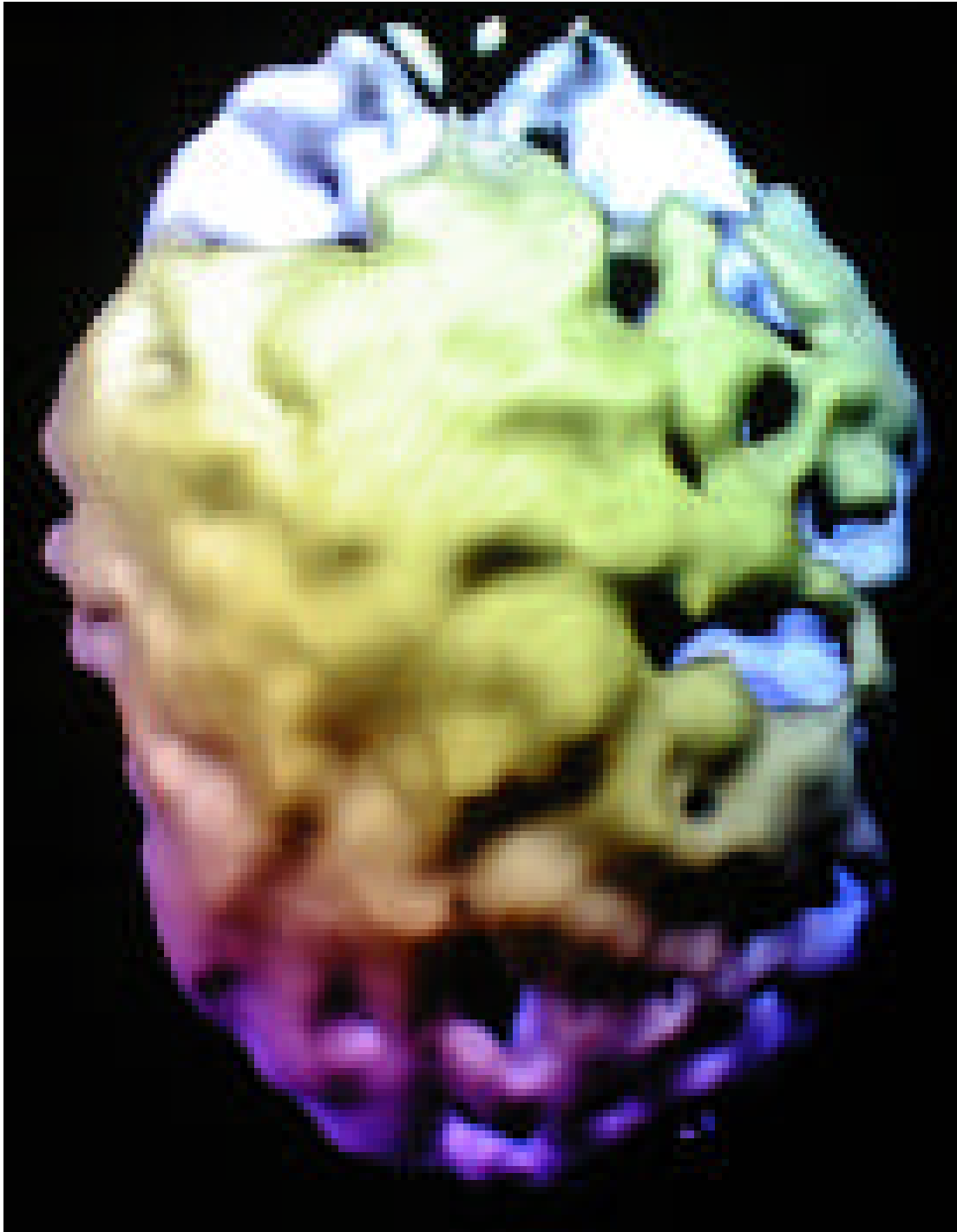

*underside surface view, NO MEDS
very poor pfc activity*



*underside surface view, with Adderall
improved pfc, especially on left side*

**15 year old male, with a serious head injury,
convicted of raping his girlfriend.**



top down surface view
marked damage to the left hemisphere

Section 15

IMAGES OF ALCOHOL AND DRUG ABUSE

Brain Pollution and the Real Reason You Shouldn't Use

Studying the effects of drugs and alcohol on the brain has clearly been one of the most informative and fascinating parts of my work. I had a sense growing up that drugs and alcohol weren't helpful to my overall health. I might add, this notion was helped along by getting drunk on a six pack of Michelob and half a bottle of champagne when I was sixteen years old – I was sick for three days. After that, I've been lucky enough to stay away from drugs and alcohol. After doing this work there's no way you could get me to do marijuana, heroin, cocaine, methamphetamine, LSD, PCP, inhalants or any more than a glass or two of wine or beer. These substances damage the patterns in your brain, and without your brain you are not you.

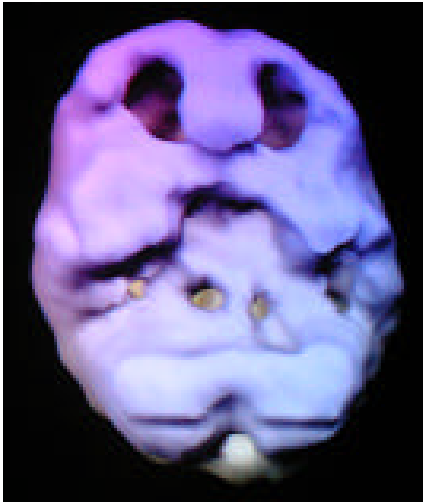
There is really quite a bit of scientific literature on the physiological effects of drugs and alcohol on the brain. SPECT has demonstrated a number of abnormalities in substance abusers in brain areas known to be involved in behavior, such as the frontal and temporal lobes. There are some SPECT similarities and differences between the damage we see caused by the different substances of abuse. I'll discuss the differences in drug abuse patterns below. There tends to be several similarities seen among classes of abused drugs. The most common similarity among drug and alcohol abusers is that the brain has an overall toxic look to it. In general, the SPECT studies look less active, more shriveled, and overall less healthy. A "scalloping effect" is common amongst drug abusing brains. Normal brain patterns show smooth activity across the cortical surface. Scalloping is a wavy, rough sea-like look on the brain's surface. I also see this pattern in patients who have been exposed to toxic fumes or oxygen deprivation. My research assistant says that the drug brains she has seen look like someone poured acid on the brain. Not a pretty site.

SPECT can be helpful in evaluating the effects of drugs and alcohol on the brain. On 3D surface images several substances of abuse appear to show consistent patterns. For example, cocaine and methamphetamine abuse appear as multiple small holes across the cortical surface; heroin abuse appears as marked decreased activity across the whole cortical surface; heavy marijuana abuse shows decreased activity in the temporal lobes bilaterally and heavy alcohol abuse shows marked decreased activity throughout the brain. These findings tend to improve with abstinence, although long term use has been associated with continued SPECT deficits seen years after abstinence. SPECT can be helpful in several ways in drug and alcohol abuse. First, 3D surface SPECT images of drug and alcohol abusers can be used in drug prevention education. Second, SPECT

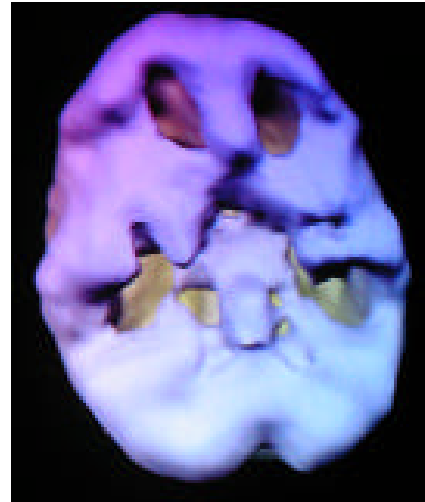
studies can help break through the denial that often accompanies substance abuse. When one is faced with their own abnormal cerebral perfusion it is hard to remain in denial. Third, SPECT may help evaluate if there is an underlying neuropsychiatric condition that needs treatment.

Marijuana

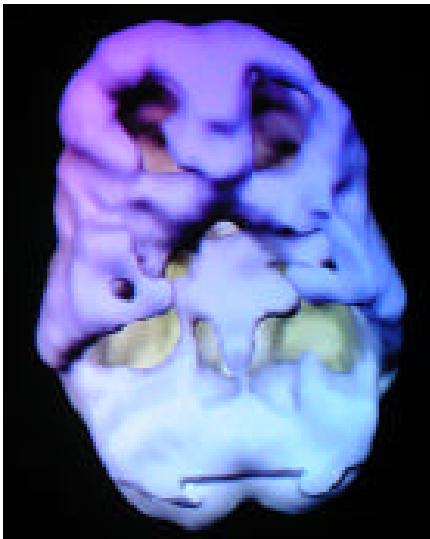In our experience, marijuana usage typically causes decreased activity in the posterior temporal lobes bilaterally. The damage can be mild or severe, depending on how long a person used, how much use occurred, what other substances were used (nicotine is a powerful vasoconstrictor) and how vulnerable a particular brain is. For more information see Dr. Amen's article High Resolution Brain SPECT Imaging in Marijuana Smokers with AD/HD, Journal of Psychoactive Drugs, Volume 30, No. 2 April-June 1998. Pgs 1-13.



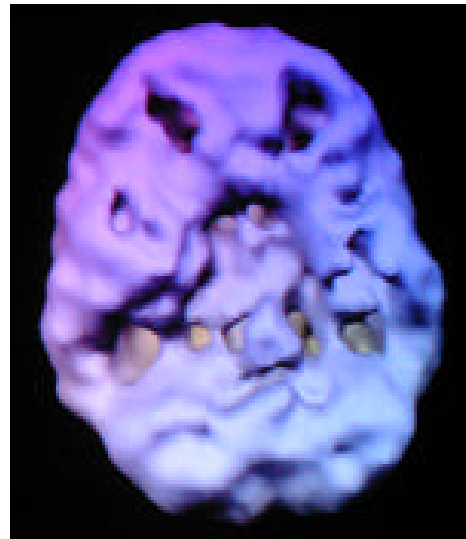
18 y/o – 3 year history of 4 x week use
underside surface view
decreased pfc and temporal lobe activity



16 y/o -- 2 year history of daily abuse
underside surface view
prefrontal and temporal lobe activity

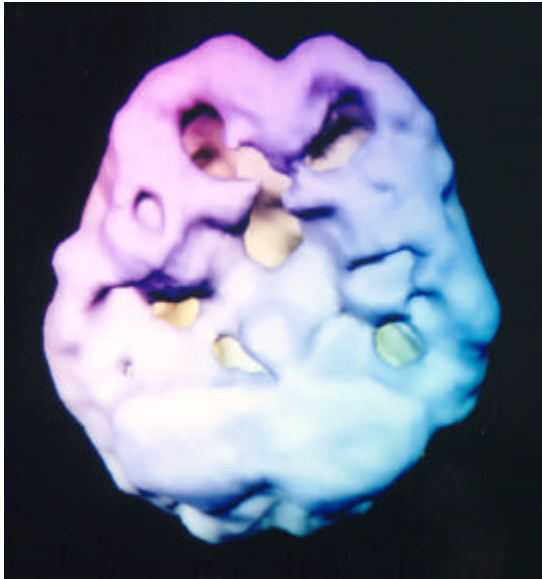


38 y/o -- 12 years of daily use
underside surface view
decreased pfc and temporal lobe activity

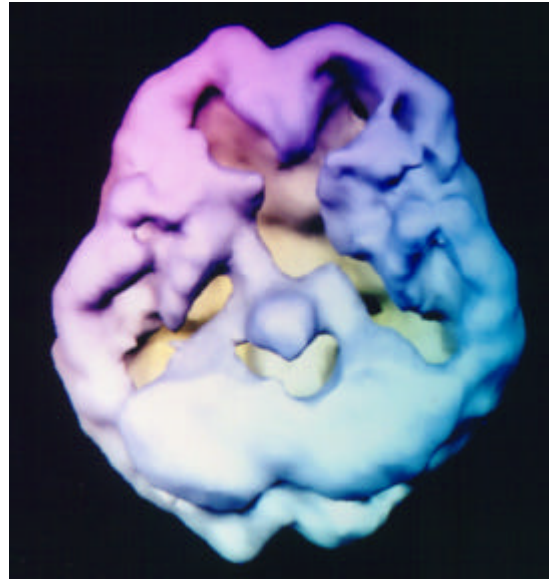


28 y/o -- 10 years of mostly weekend use
underside surface view
decreased pfc and temporal lobe activity

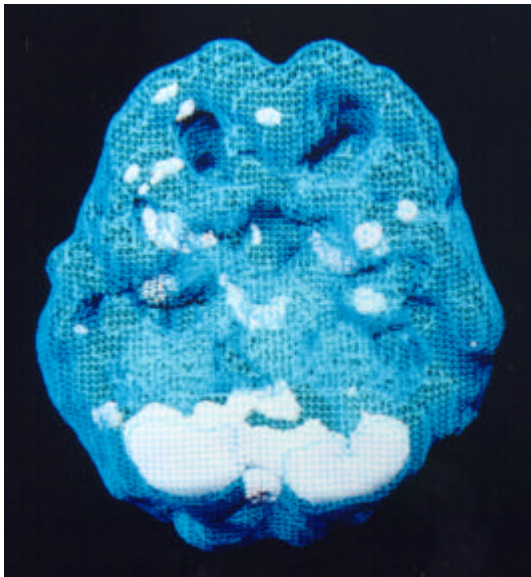
Off and On Marijuana



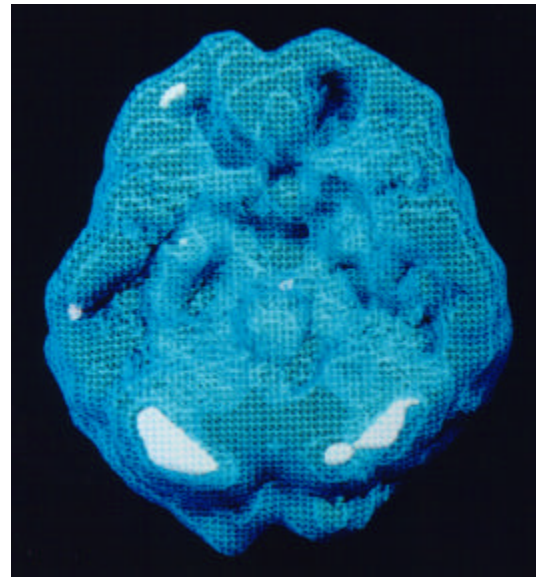
underside surface view, off THC
decreased pfc and temporal lobe activity



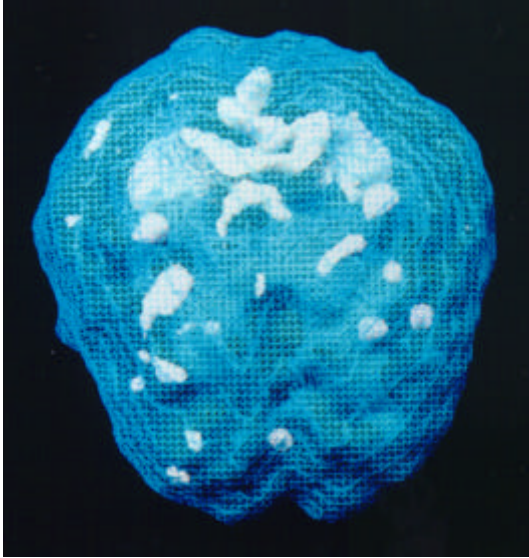
underside surface view, on THC
severe overall decreased activity



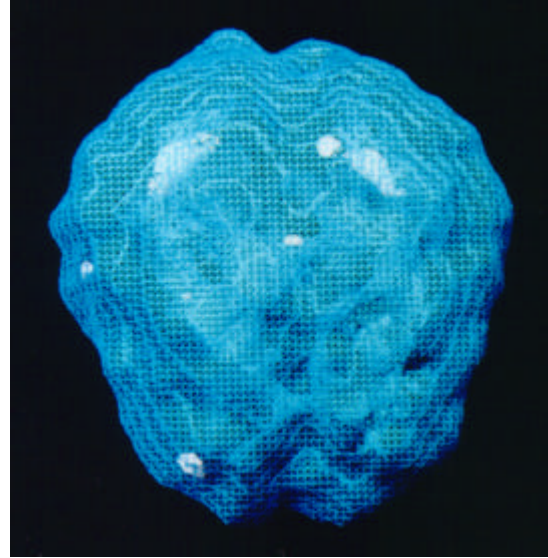
underside active view, off THC
increased deep left temporal lobe activity



underside active view, on THC
overall calming of activity



top-down active view, off THC
patchy increased uptake



top-down active view, on THC
overall calming of activity

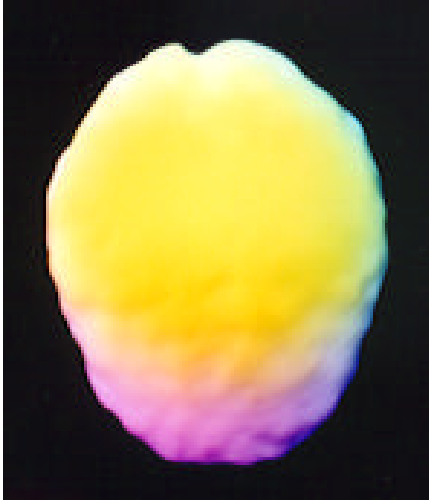
This 57-year-old physician had abused marijuana for 30 years. We performed this SPECT series because he had been unable to stop using without feeling very angry, irritable, agitated and anxious.

The first study (those images in the right column) was performed after he came to the clinic intoxicated from 3 straight days of heavy usage. The second study (those images in the left column) was performed after he abstained from marijuana usage for 1 month.

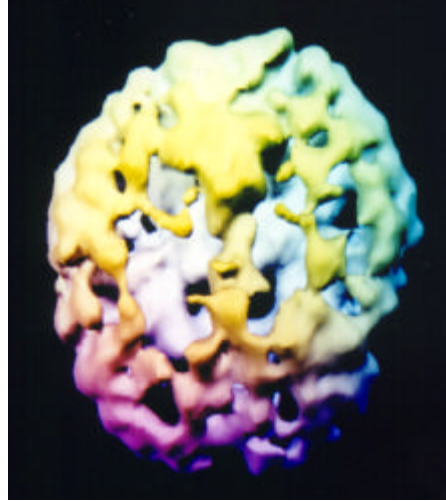
Notice the study without marijuana shows decreased temporal lobe activity (likely from the chronic marijuana usage), but also patchy increased uptake, especially increased activity in the deep left temporal lobe (often associated with anger, irritability and anxiety). The study with heavy marijuana usage shows marked overall decreased activity, especially in the prefrontal cortex and temporal lobes (associated with attention, memory and motivational problems) but also there is a decrease in the overactive areas noted in the “off marijuana” study.

This scan series argues for the possibility of “self-medication,” but unfortunately this medication has the side effect of causing the potential for long term damage to his brain

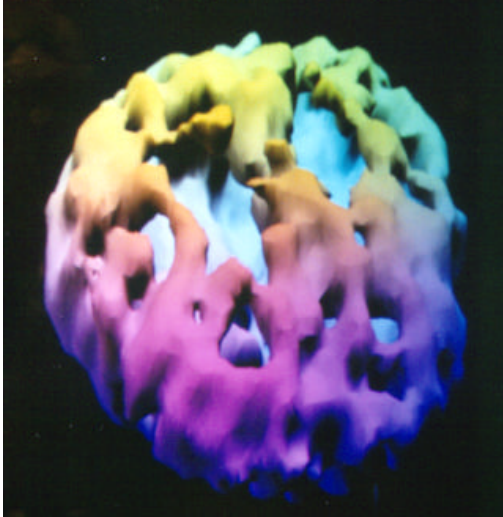Heroin & Methadone



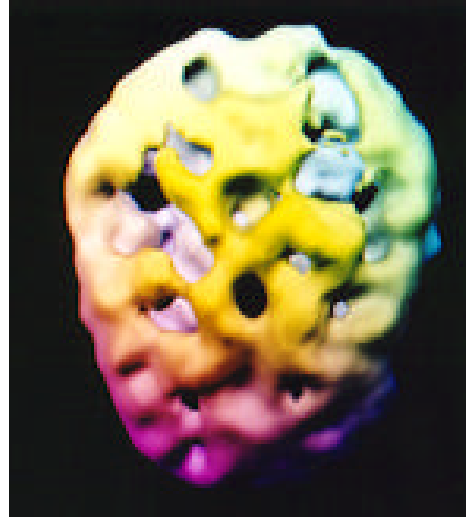
Normal view
top down surface view
full, symmetrical activity



39 y/o -- 25 yr hx of frequent heroin use
top down surface view
marked overall decreased activity

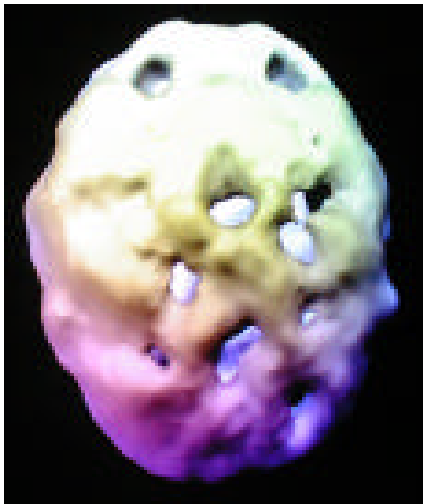

39 y/o -- 25 yrs of frequent heroin use
front on surface view
marked overall decreased activity

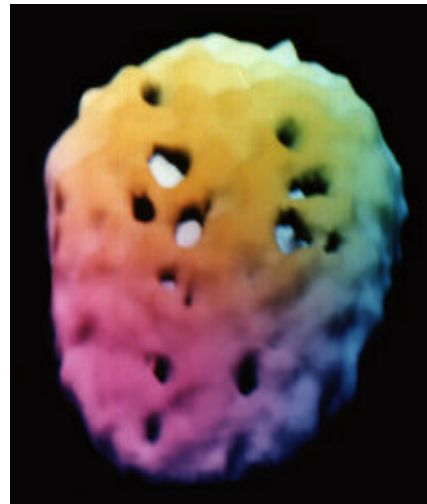


40 y/o, 7 yrs on methadone
heroin 10 yrs prior
top down surface view
marked decreased overall activity

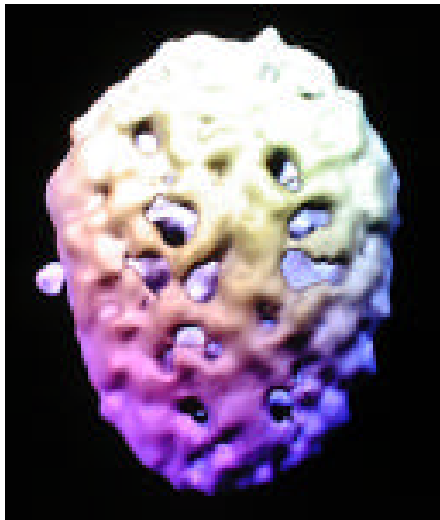
Cocaine & Methamphetamine



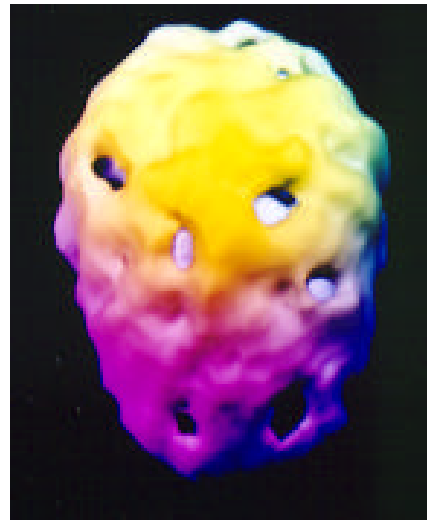52 y/o – 28 yr hx frequent meth use
top down surface view
multiple holes across cortical surface



24 y/o -- 2 yr hx of frequent cocaine use
top down surface view
multiple holes across cortical surface



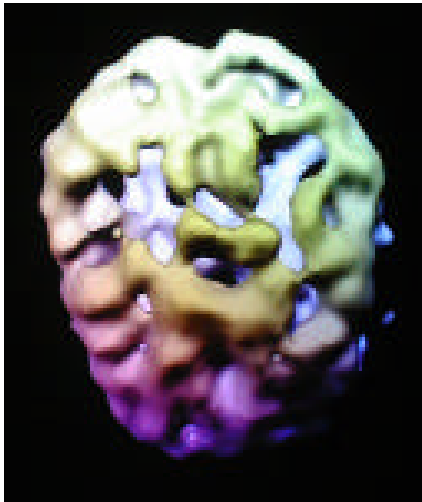
28 y/o – 8 yrs heavy meth use
front on surface view
marked overall decreased activity



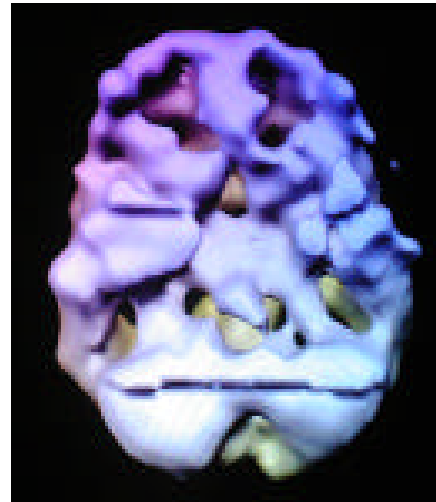
36 y/o, 10 years frequent meth
top down surface view
multiple holes across cortical surface

Alcohol

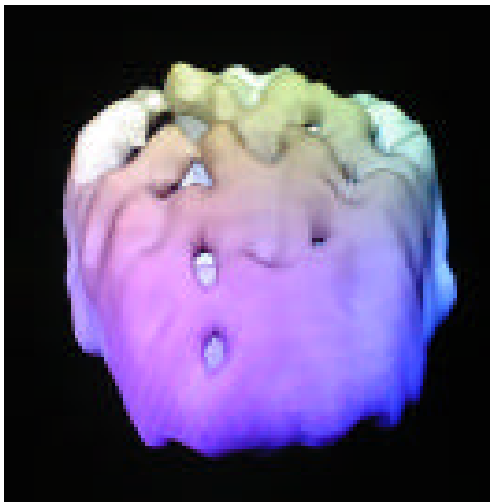38 y/o – 17 years of heavy weekend use



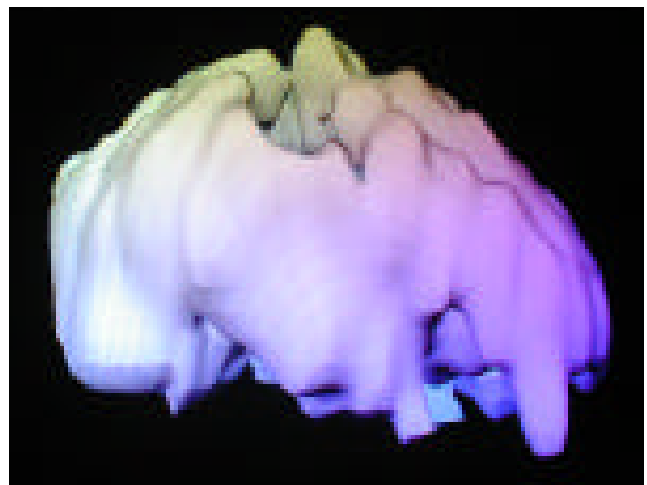underside surface view



underside surface view



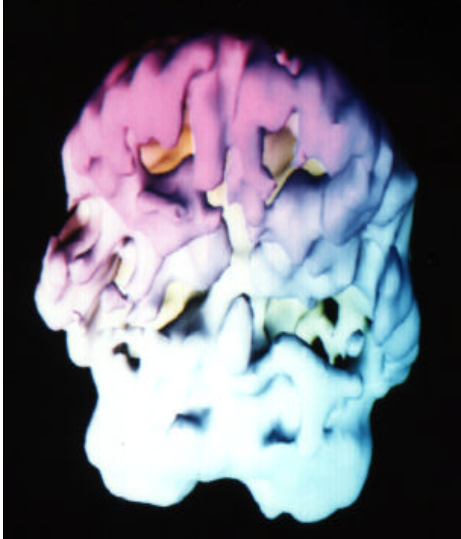
front on surface view



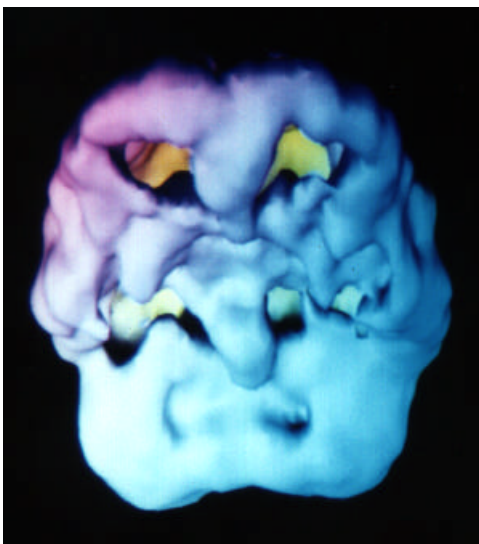
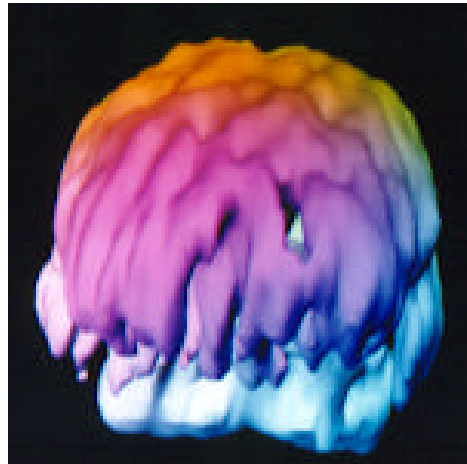right side surface view

marked overall decreased activity

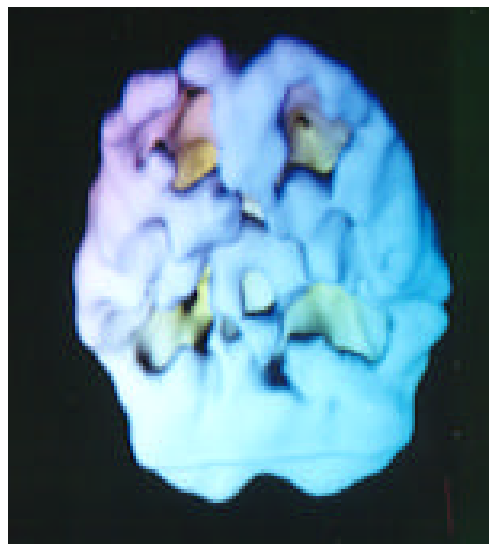
Alcohol



48 y/o -- 22 years of daily use with history of past head injury
underside surface view
marked scalloping overall decreased activity

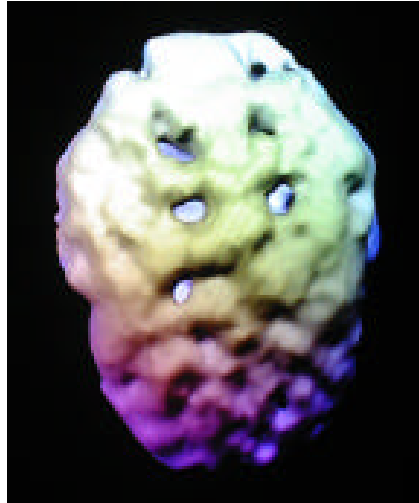

44 y/o -- 18 years of daily use
underside surface view
marked overall decreased activity

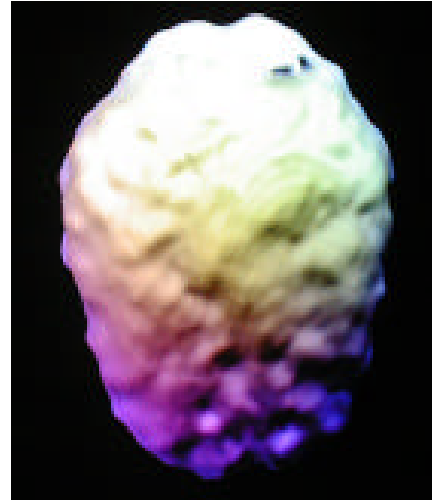

45 y/o -- 25 year history of daily abuse
underside surface view
marked overall decreased activity

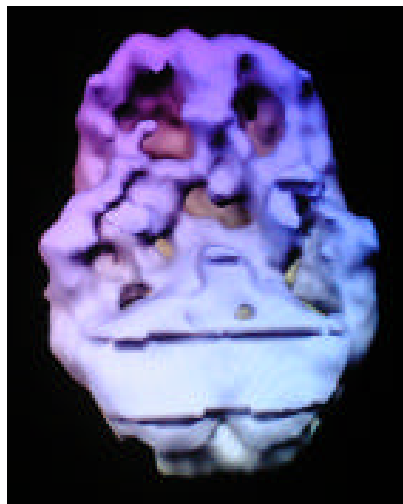
Hope for Healing Alcohol, Cocaine & Meth On and Off Drugs



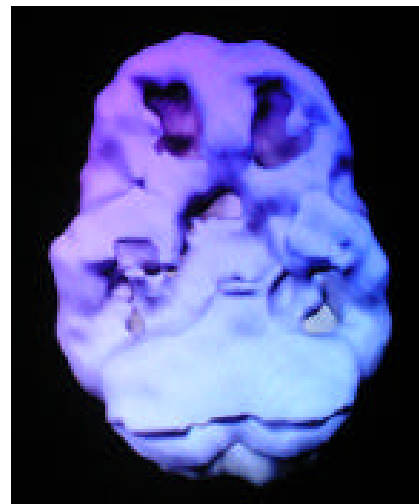
*top-down surface view
during substance abuse*



*top-down surface view
a year drug and alcohol free*



*underside surface view
during substance abuse*

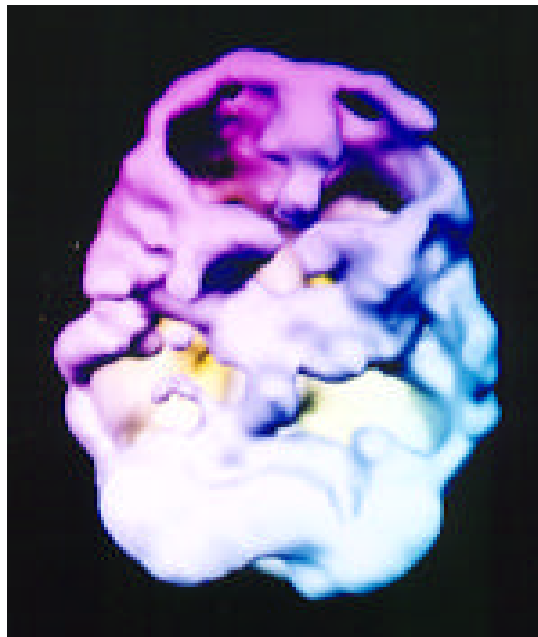


*underside surface view
a year drug and alcohol free*

notice the overall holes and shriveled appearance during
abuse and marked improvement with abstinence

Heavy Nicotine & Caffeine Abuse

**45 y/o -- 27 year history of heavy use
3 packs of cigarettes and 3 pots of coffee daily**



undersurface view
marked decreased overall activity

Section 16

IMAGES OF TREATMENT

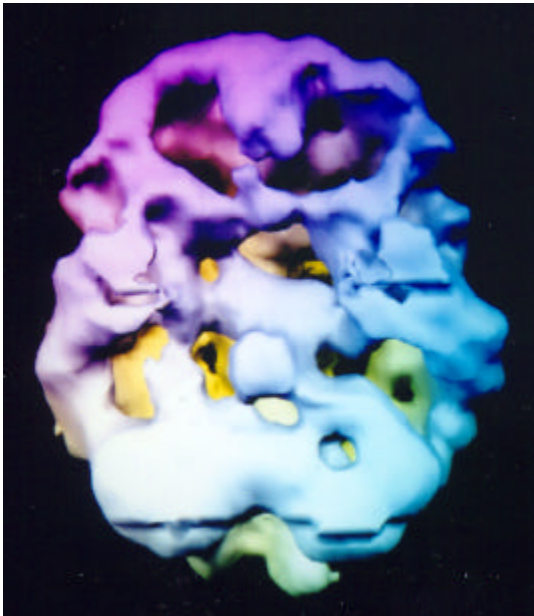
Hope for Healing

This is perhaps the most important section of this atlas. It shows actual images of treatment, the before and after SPECT images of our patients who have experienced significant benefit from treatment. This section highlights that in many cases the brain can be healed or optimized to produce greater function and subsequently a healthier, happier life.

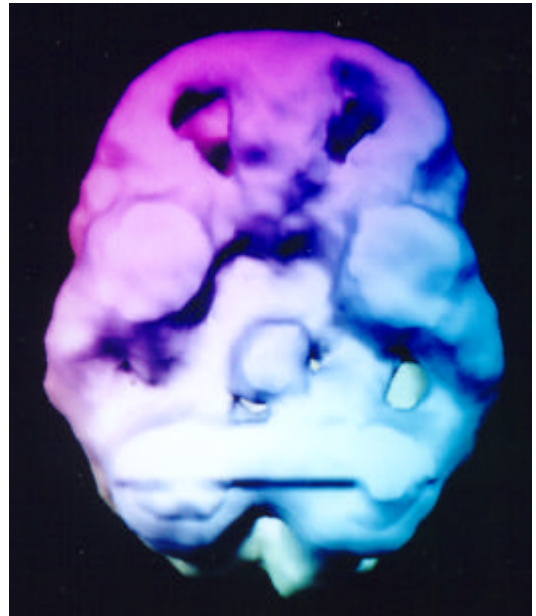
The opening case history is one that was listed in a previous section. It is such an important and instructive case study that it warrants repeating.

A 35-year-old man who had been living on the street was brought for evaluation by his mother. He had previously been diagnosed on many occasions with paranoid schizophrenia, but refused medication. His SPECT study revealed marked overall decreased activity throughout the cerebral cortex. Being able to see his own brain activity, represented by the 3D surface SPECT study above, was helpful for him. He agreed to take his medication under his mother's supervision. One month later, after significant clinical improvement on 4 mg of risperidone a day a repeat SPECT study was performed which showed improved overall cerebral perfusion. Being able to see the before and after SPECT studies side by side on the imaging computer monitor again was very encouraging to the patient and helped significantly with compliance.

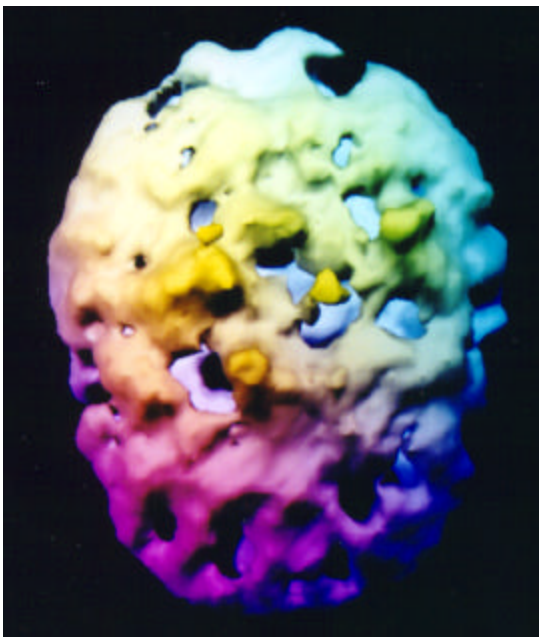
Paranoid Schizophrenia Before and After Risperdal



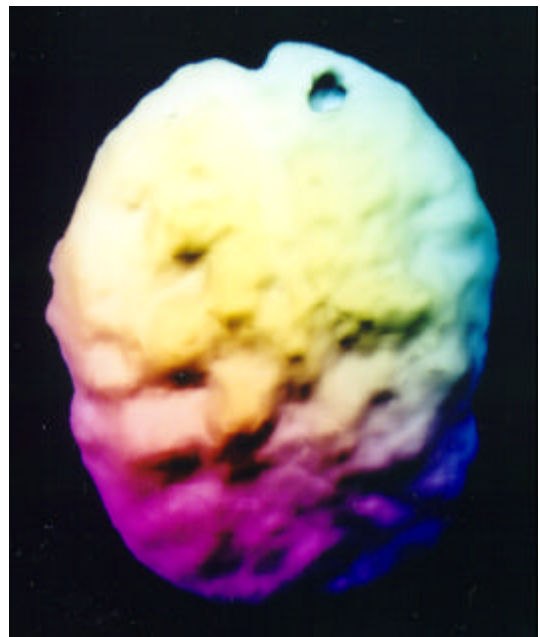
underside surface view, NO MEDS
very poor overall activity



underside surface view, W/MEDS
marked overall improvement




top down surface view, NO MEDS
very poor overall activity

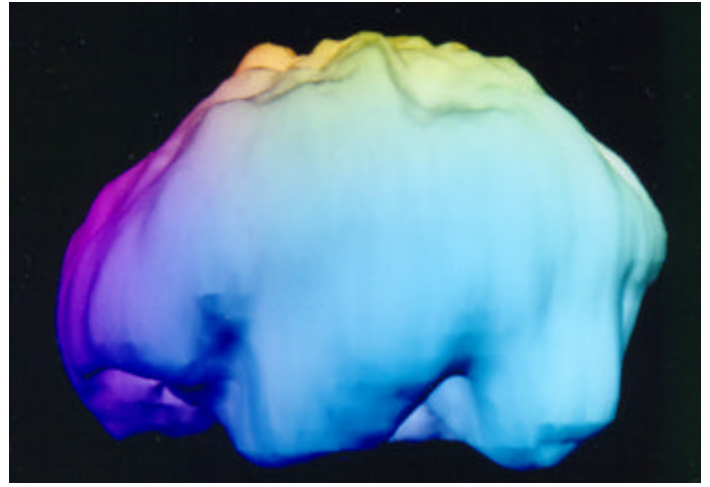


top down surface view, W/MEDS
marked overall improvement

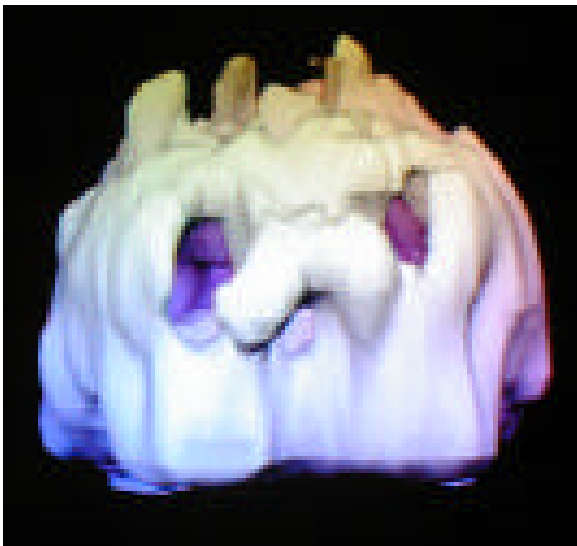Paranoid Schizophrenia Before and After Risperdal (con't)



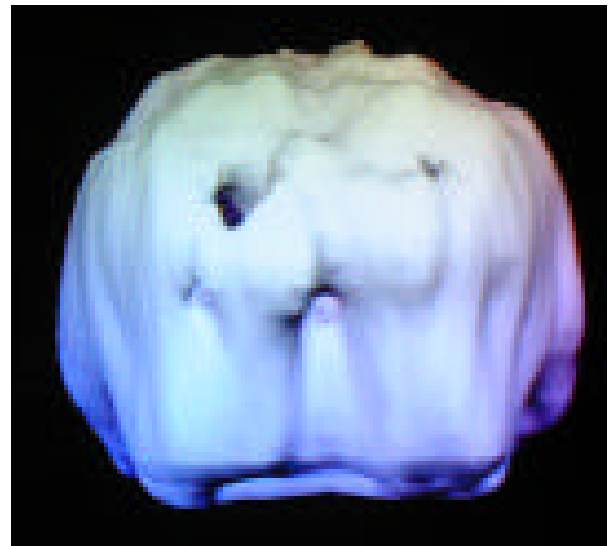
left side surface view, NO MEDS
very poor overall activity



left side surface view, W/MEDS
marked overall improvement



left side surface view, NO MEDS
very poor overall activity

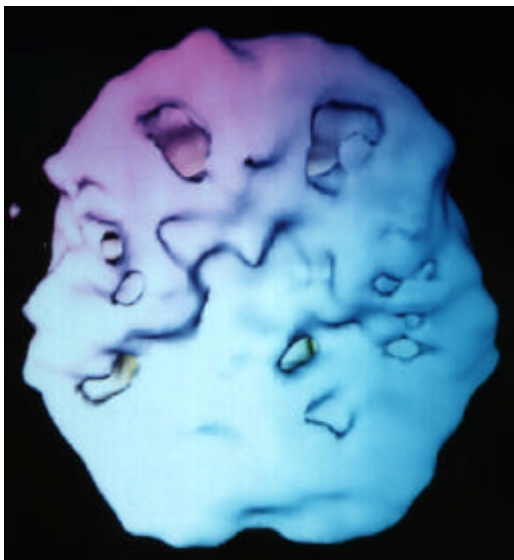

left side surface view, W/MEDS
marked overall improvement

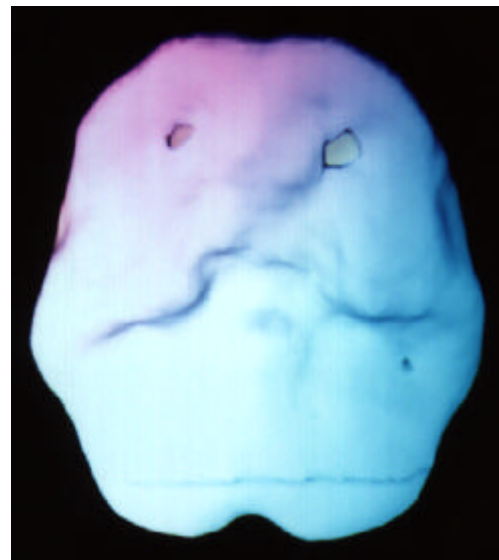
Suicidal, Rage Before and After Anafranil

Bob, a 48 year old married system analyst, came to see me because he had a problems with holding grudges, "getting stuck" into loops of negative thinking patterns, obsessive thoughts, moodiness, irritability, periodic intense suicidal thoughts and problems with anger control. "I am the anger broker of the valley," he reported during the initial session. His wife also reported episodes where Bob would often become upset about something, be unable to shift away from the thoughts which were upsetting him, lose control and exhibit aggressive behavior such as breaking furniture or putting holes in the walls. Bob had a childhood history of oppositional behavior (by the report of his mother). As part of his evaluation a brain SPECT study done which showed marked increased uptake in his cingulate gyrus. I started him on Anafranil (clomipramine), which has been used in patients with obsessive thinking. Over two months of treatment the dose of Anafranil was increased to 225 mg. a day. Bob and his family noted a marked positive response. He was less irritable, markedly less aggressive, more flexible and happier. He reported that he was more effective in interpersonal relationships, especially with his children.

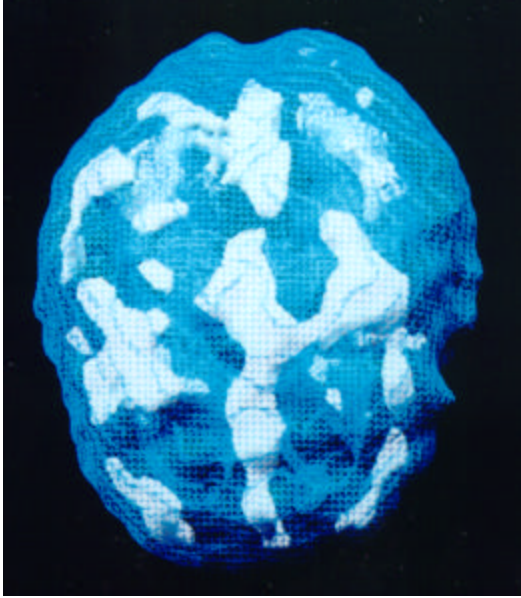
After three years of continued clinical improvement on the same dose of clomipramine (2 brief trials at lowering the dosage caused a resumption of symptoms) a follow up brain SPECT study was ordered to evaluate brain activity subsequent to treatment. The follow up SPECT study revealed a marked normalization of brain activity.



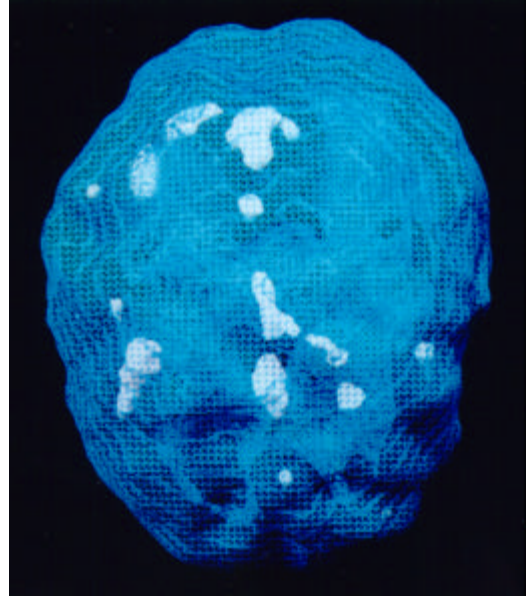
underside surface view, NO MEDS
very poor pfc/temp lobe activity



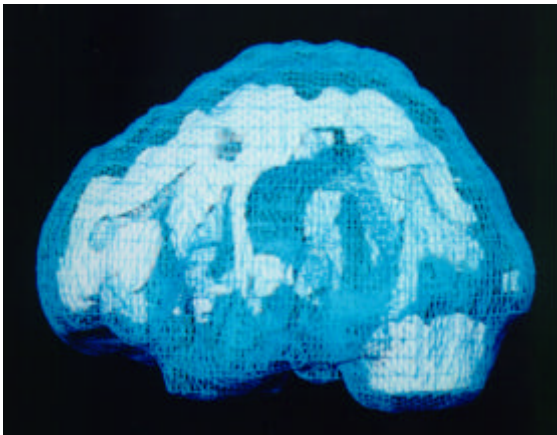
underside surface view, W/MEDS
normalization of activity



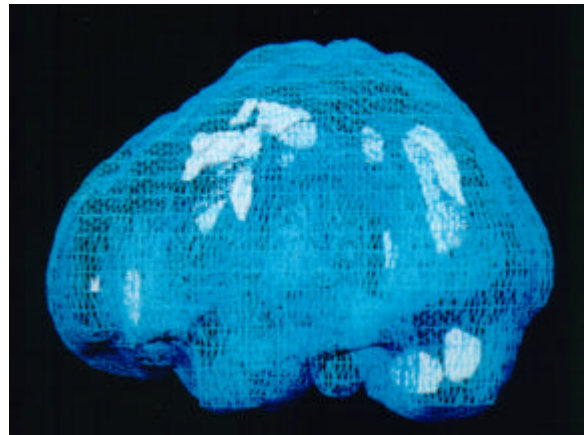
top-down active view, NO MEDS
marked increased cingulate and
left temporal lobe activity



top-down active view, W/MEDS
overall improved activity



left side active view, NO MEDS
marked increased cingulate and
left temporal lobe activity



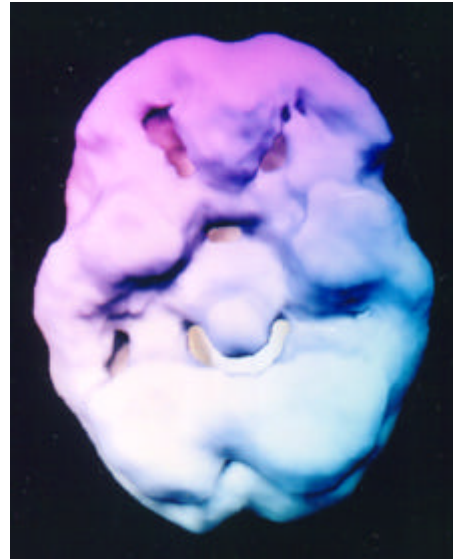
left side active view, W/MEDS
overall improved activity

Anger, ADD

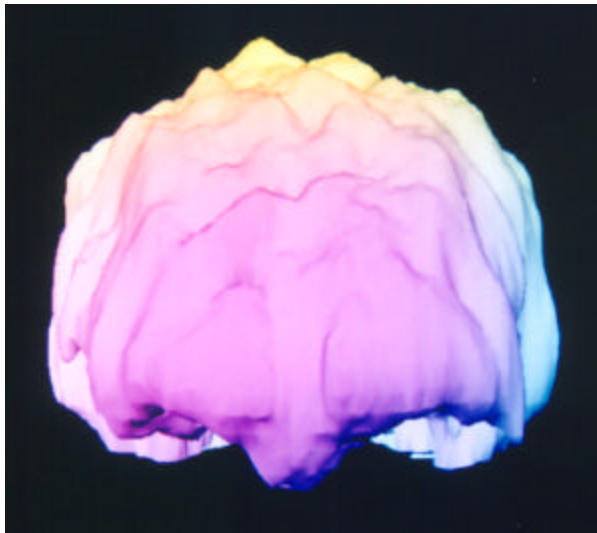B/A Depakote and Adderall



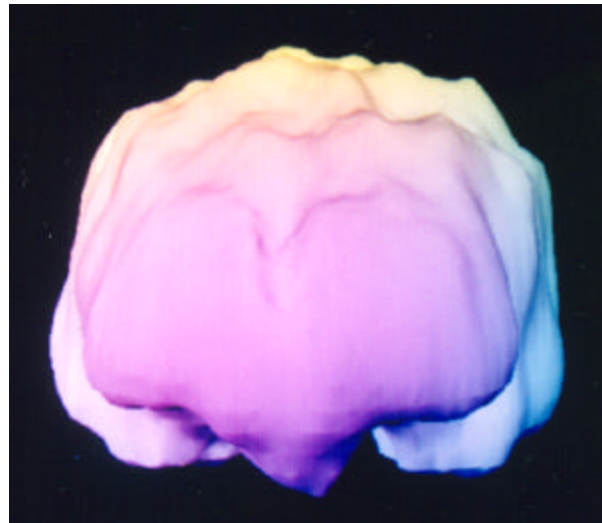underside surface view, NO MEDS
very poor pfc/temp lobe activity



underside surface view, W/MEDS
normalization of activity



front on surface view, NO MEDS
overall shriveling of activity

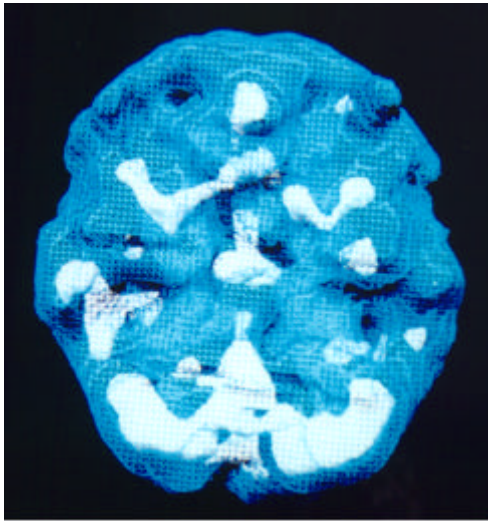


front on surface view, W/MEDS
overall improved activity

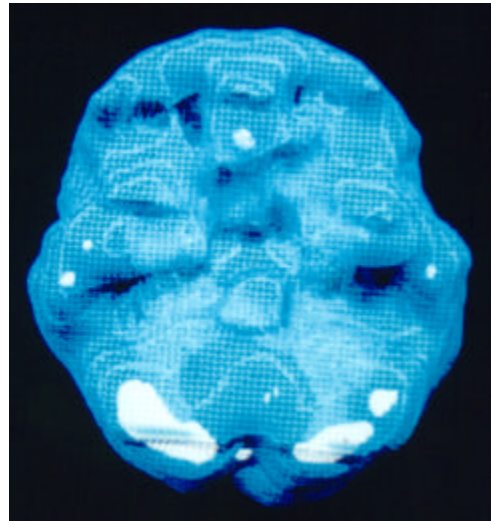
Mark, a 52 year old married accountant, sought help for problems with concentration, focus, follow through and severe temper problems. He had become physically aggressive on several occasions with his wife. He tended to take things in a negative way and struggled with his memory. Often, for little reason he would explode and then feel very guilty about his behavior a short while later. He had longstanding school problems, despite getting an MBA degree. After his initial evaluation he was diagnosed with attention deficit disorder and a SPECT was ordered to rule out temporal lobe dysfunction. The SPECT study showed marked overall decreased activity, especially in the prefrontal cortex and temporal lobes. He was placed on a combination of Adderall (for ADD) and Depakote (for temper). He had a very positive response to medication. He and his wife reported that he was more focused, better able to follow through on tasks, less irritable and in much better control of his temper. After three years of continued clinical improvement on the same dose of Depakote and Adderall a follow up brain SPECT study was ordered to evaluate brain activity subsequent to treatment. The follow up SPECT study revealed a marked normalization of brain activity.

PTSD, Depression and Anxiety Before and After St. John's Wort and EMDR

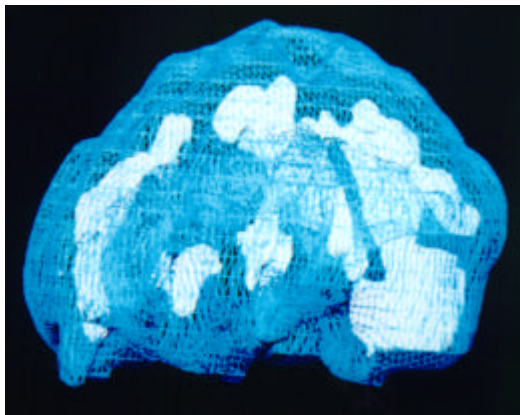
Linda was 26 years old when she first came to see me. She had a history of 2 prior violent rapes (age 15 & 22), a physically abusive love relationship, along with experiencing the deaths of 8 friends (age 14-16). Her symptoms were depression, anxiety, worrying and drug use. Her baseline SPECT study showed marked overactivity in the cingulate (problems shifting attention), basal ganglia (anxiety) and limbic areas (depression and mood dyscontrol). After 4 psychotherapy sessions with EMDR (a specific treatment technique for traumatic events) and 1 month of St. John's Wort (900 milligrams a day) Linda felt significantly better. When we repeated her SPECT study there was marked normalization of activity in all 3 areas.



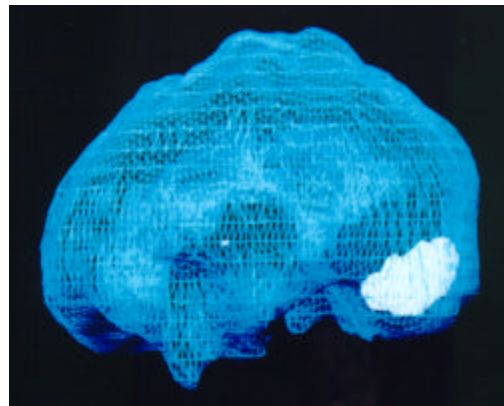
underside active view, NO MEDS



underside active view, W/MEDS



left side active view, NO MEDS

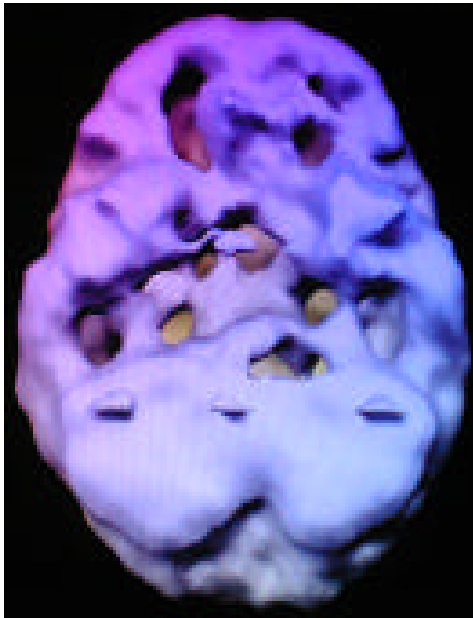


left side active view, W/MEDS

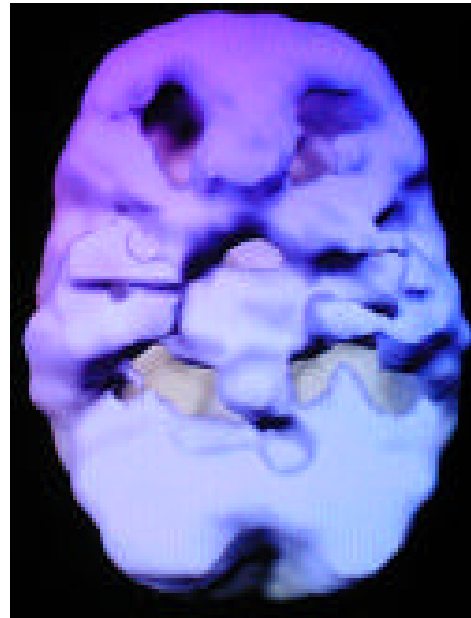
marked increased cingulate, basal ganglia and limbic activity

overall improved activity

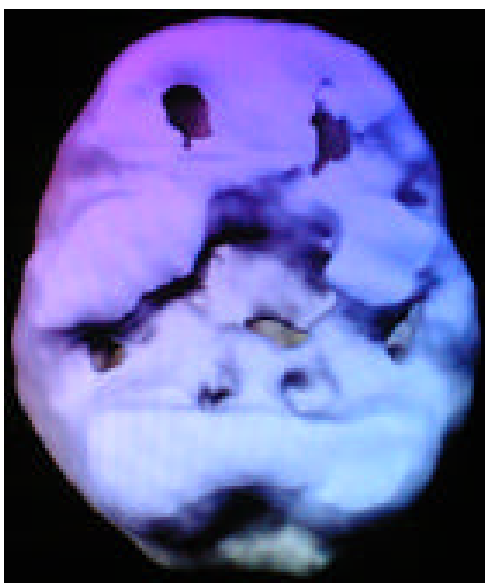
Attention Deficit Disorder Before and After Adderall



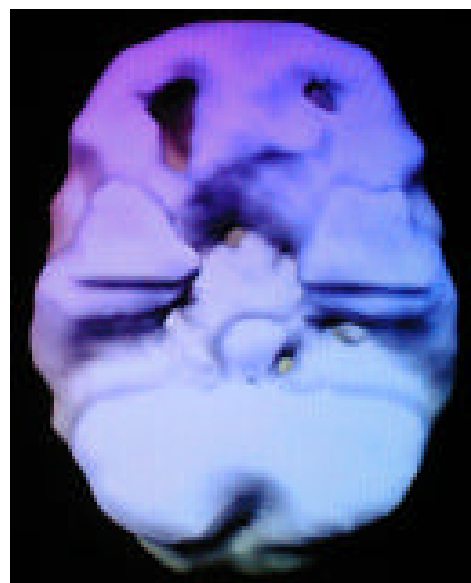
underside surface view, NO MEDS
very poor pfc and temporal lobe activity



underside surface view, NO MEDS
very poor pfc and temporal lobe activity

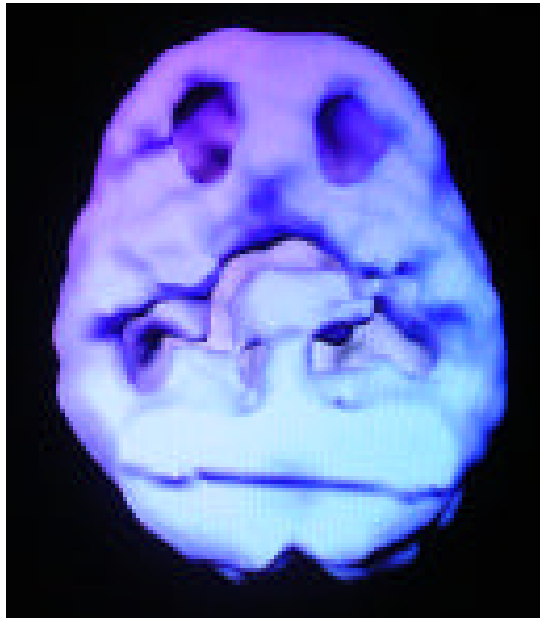


underside surface view, with Adderall
marked overall improvement

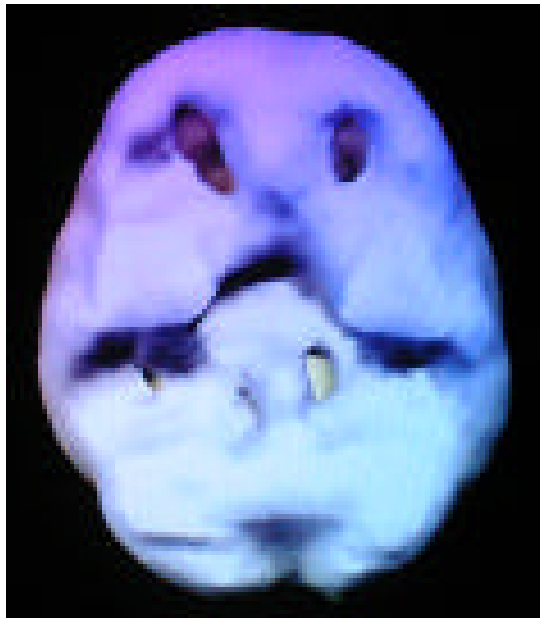

underside surface view, with Adderall
marked overall improvement

Attention Deficit Disorder Before and After Dexedrine



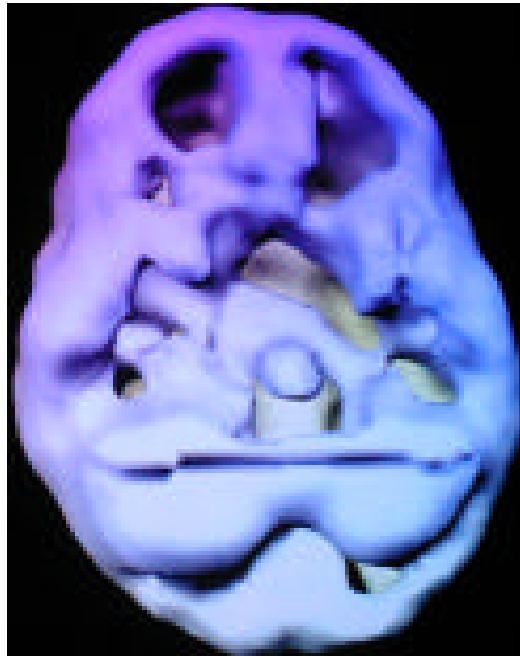underside surface view, NO MEDS
very poor pfc and temporal lobe activity



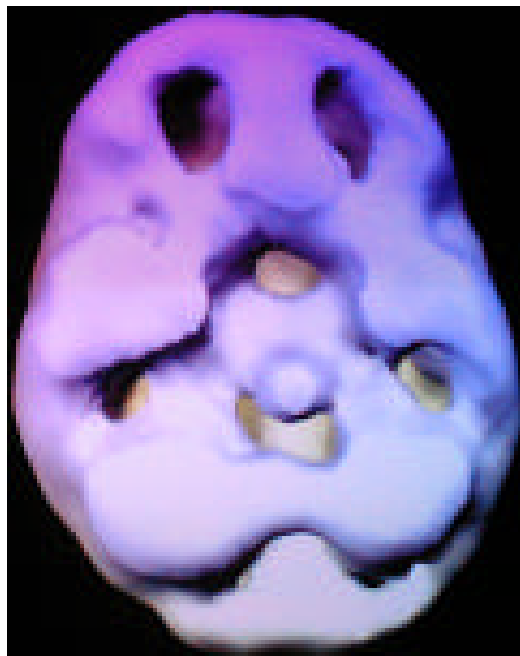
underside surface view, with Dexedrine
marked overall improvement

Conduct Disorder

Before and After Tegretol/Clonidine



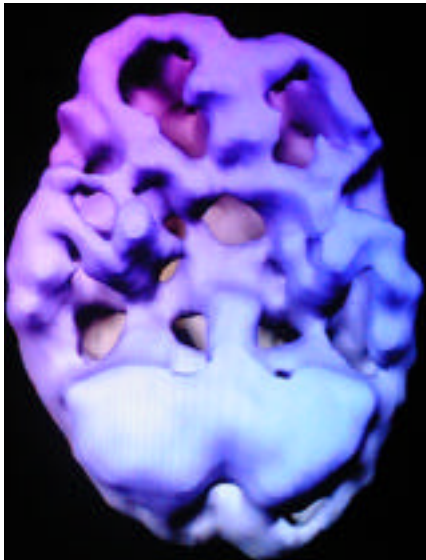
undersurface view, NO MEDS
very poor prefrontal and temporal lobe activity



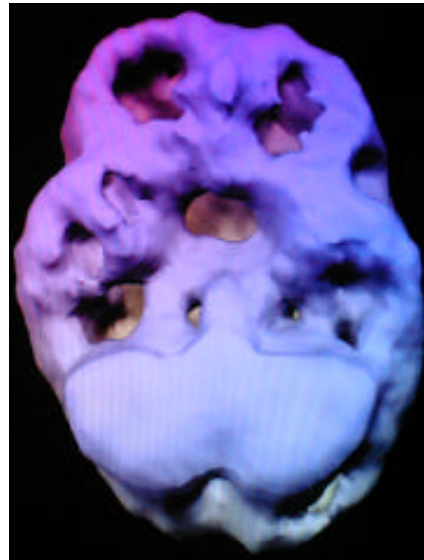
undersurface view, W/MEDS
overall improved activity

Memory, Anger, ADD B/A Adderall and Depakote

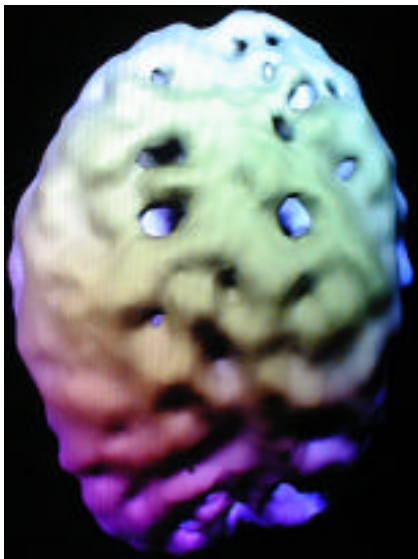
Russ had serious problems with unresponsive ADD symptoms, anger outbursts and memory problems. Here is his SPECT study before and 1 year after treatment with Adderall and Depakote.



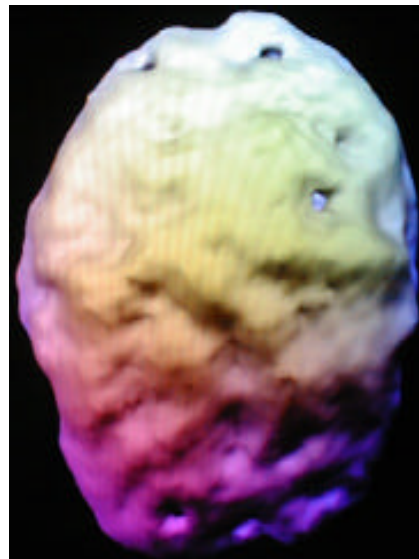underside surface view, NO MEDS
very poor pfc/temp lobe activity



underside surface view, W/MEDS
overall improvement



top down surface view, NO MEDS
overall decreased activity

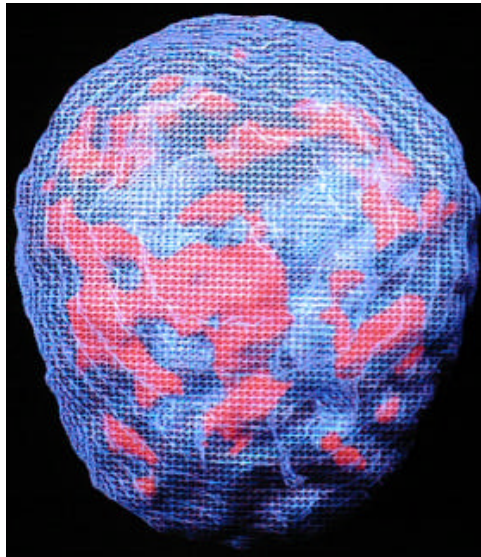


top down surface view, W/MEDS
overall improvement

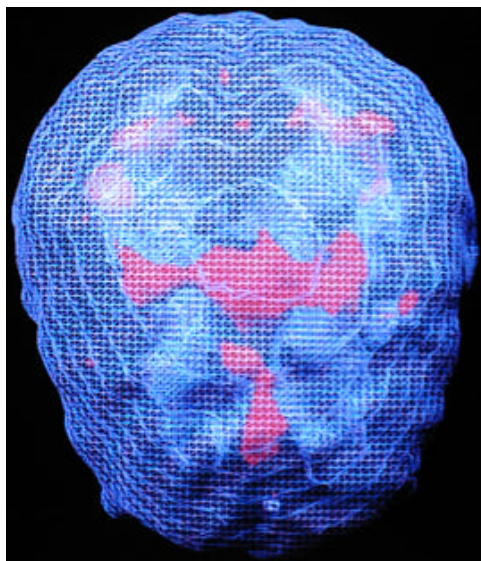
Asperger's Syndrome

B/A Zyprexa

Tim, age 12, was diagnosed with Asperger's Syndrome. He had problems with repetitive behaviors and very poor social skills. In addition, he was rigid in his thinking and had frequently temper outbursts. His baseline SPECT study revealed marked increased patchy uptake throughout his cerebral cortex. Zyprexa had an overall calming effect on his brain and significantly improved his temper and cognitive inflexibility.



top down surface view, NO MEDS
marked patchy increased uptake

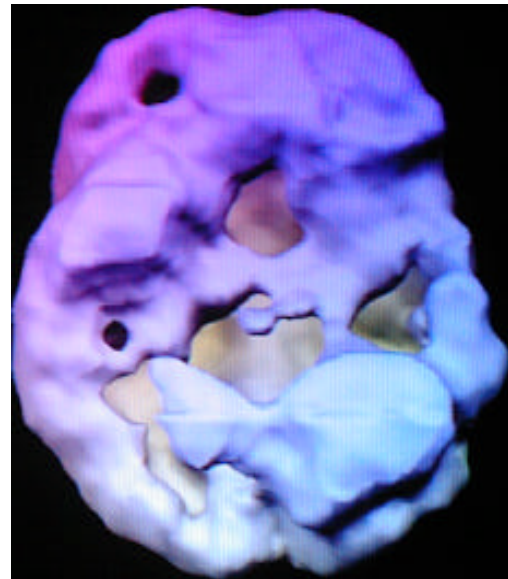


top down surface view, w/Zyprexa
overall calming effect

Severe Head Trauma

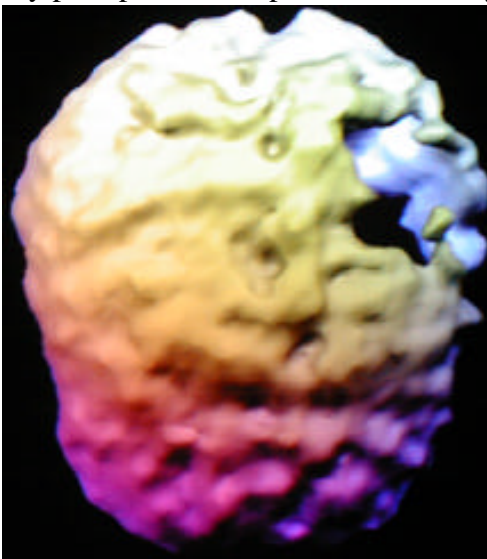
B/A Adderall

Randy, age 17, sustained a severe blow to the left side of his head. He had a subdural bleed over his left parietal lobe and subsequently developed temper problems, school problems, speech and coordination problems. This scan series was performed on and off Adderall. Note the marked overall improvement from Adderall, giving him more access to brain function.

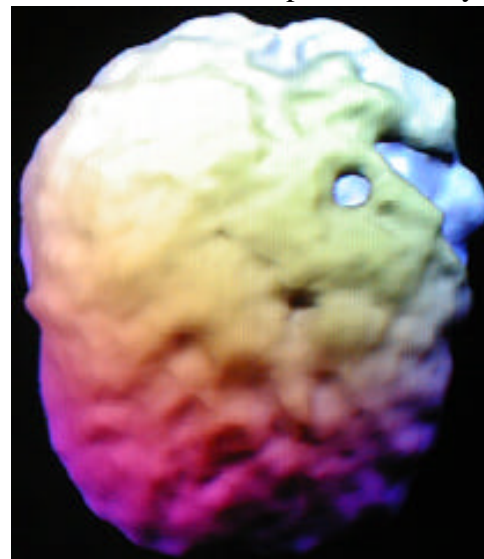


underside surface view, w/Adderall
marked overall improved activity

underside surface view, NO MEDS
very poor pfc and temporal lobe activity



top down surface view, no meds
severe decreased left parietal area

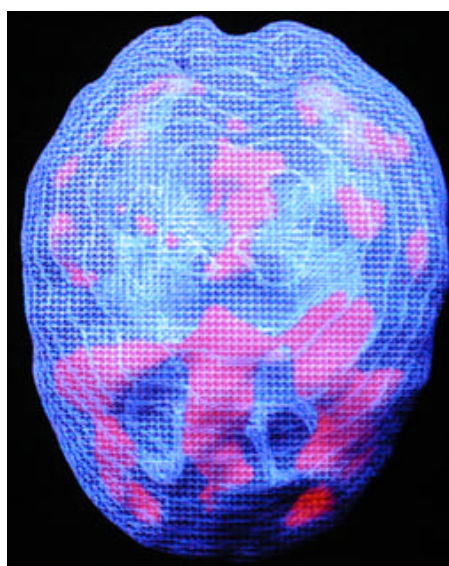


top down surface view, with Adderall
overall enhanced activity

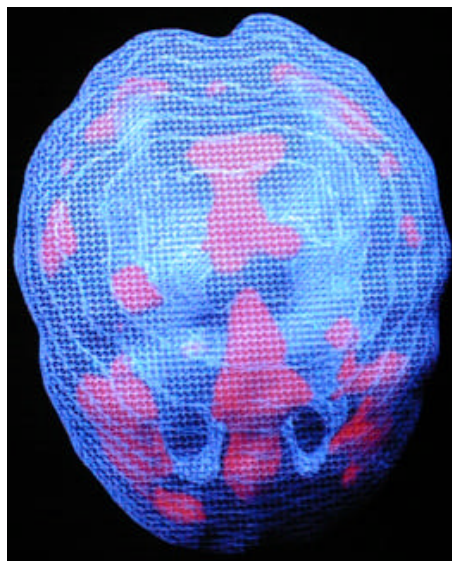
Anger/Severe ODD

B/A Risperdal

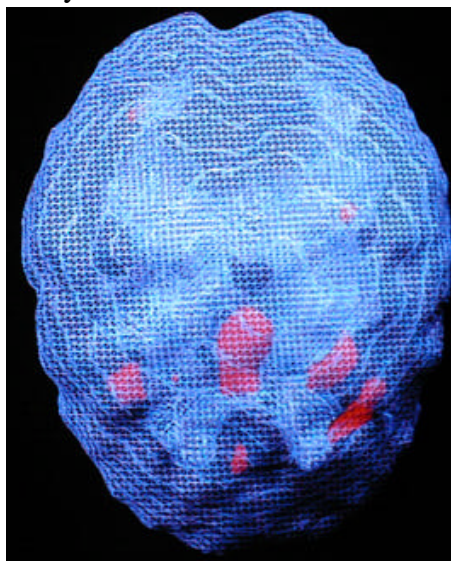
Mark, a 14 y/o male, was evaluated for anger outbursts and constant defiant behavior. Psychotherapy and parent training were ineffective. Depakote, Ritalin, Dexedrine and Wellbutrin were also ineffective. Prozac made him much more aggressive. A SPECT study revealed marked hyperfrontality and he was placed on Risperdal. He had a dramatic response. He was more compliant, happier and less aggressive. Two follow up studies were performed a month and 6 months later, which revealed progressive calming of the hyperfrontality.



top down active view
note marked hyperfrontality



mild decrease in hyperfrontality



marked decrease in hyperfrontality